

# **ORTHOPAEDICS/ RHEUMATOLOGY**

Papers held at Congresses 1995 – 2001

# ACCEPTED ABSTRACTS 1995 - 2000

English / German

	Page
Erste Erfahrungen mit der extrakorporalen Stosswellentherapie bei therapieresistenter Tendinosis calcarea (Dr. F. Bernhard, Bremen, Germany)	5
Shock waves employment in Orthopaedics and traumatology (Dr. L. Felli, Genova, Italy)	7
A pilot investigation into the action of low-energy shock waves on impaired muscular function in children with cerebral palsy and low-back pain in adults (Dr. H. Lohse-Busch, Bad Krozingen, Germany)	9
Treatment of non unions with shock waves with special reference to carpal scaphoid non union (Dr. S. Russo, Napoli, Italy)	10
Tendinitis calcarea of the shoulder - a prospective clinical and MR controlled study of 42 patients treated by extracorporeal shock waves (Dr. M. Maier, München, Germany)	14
Kernspintomographische Veränderungen der Schulterregion nach Stosswellentherapie bei der Tendinitis calcarea (Dr. M. Maier, München, Germany)	16
Pilotuntersuchung zur Wirkung von nichtfokussierten, extrakorporalen Stosswellen auf Muskelfunktionsstörungen bei Kindern mit infantiler Zerebralparese (Dr. H. Lohse-Busch, Bad Krozingen, Germany)	18
Behandlungsergebnisse der mittelenergetischen Stosswellentherapie bei Tendinosis calcarea (Dr. T. Wallny, Bonn, Germany)	20
Die niederenergetische ESWT in der Behandlung der Epicondylitis humeri radialis (Dr. T. Wallny, Bonn, Germany)	21

Niederenergetische ESWT bei chronischem Tennisellenbogen - sind die Ergebnisse geräteabhängig ? (Dr. O. Krischek, Mainz, Germany)	22
Erste Ergebnisse zum Einsatz der extrakorporalen Stosswellentherapie in der Sportorthopädie (Dr. H. Lohrer, Frankfurt a.M., Germany)	24
Therapieresistente Ansatzdendinosen - Indikation zur ESWT oder zur Operation? (Dr. C. von Hasselbach, Essen, Germany)	26
Die extrakorporale Stosswellentherapie (ESWT) am Bewegungs- Apparat: Erste Erfahrungen/Resultate (Dr. B. Dubs, Zürich, Switzerland)	28
Behandlungsergebnisse der extrakorporalen Stosswellentherapie (ESWT) in der Sportorthopädie (Dr. J. Schöll, Frankfurt a.M., Germany)	30
Therapieresistente Ansatzdendinosen, Indikation zur ESW Therapie oder zur OP? (Dr. Ch. von Hasselbach, Essen, Germany)	31
Extrakorporale Stosswellentherapie bei Heel Pain (Dr. F.O. Steeb, Stuttgart, Germany)	33
Untersuchung zum Wirkmechanismus der niederenergetischen extrakorporalen Stosswellentherapie (ESWT) im Modell der Ratte (Dr. M. Haake, Marburg, Germany)	34
The use of extracorporeal shock wave therapy in the treatment of heel pain (Dr. F.O. Steeb, Stuttgart, Germany)	35
Treatment of the epicondylopathia radialis with extracorporeal shock wave therapy – preliminary results (Dr. R. de Oya, Madrid, Spain)	36
Clinical Results in extracorporeal induced lithotripsy of tendinosis calcareo of the shoulder (Dr. A. Brade, Remscheid, Germany)	37

The treatment of non-union by high energy shock wave therapy (Dr. C. de Durante, Napoly, Italy)	38
Tendinosis calcarea der Schulter: Ist die ESWT eine Alternative ? (Dr. B. Dubs, Zürich, Switzerland)	40
Dispergierende extrakorporale Stosswellentherapie bei Muskelfunktionsstörungen (Dr. H. Lohse-Busch, Bad Krozingen, Germany)	42
Einfluss „niederenergetischer“ ESWT auf Neurotransmitter und endogene Opioide (Dr. M. Haake, Marburg, Germany)	44
Die ESWT im Rahmen der orthopädischen Schmerztherapie: 2-Jahres Ergebnisse in 899 Fällen (Dr. W. Brunner, Mainburg, Germany)	45
Treatment of humeral epicondylitis with low energy shock waves (Dr. S. Gigliotti, Napoli, Italy)	46
Ten years experience with shock wave therapy of radial and ulnar epicondylar disorders (Dr. J. Haist, Wörrstadt, Germany)	47
Three years results of extracorporeal shock wave therapy (ESWT) with 272 amateur and competitive athletes with epicondylitis humeri radialis (EHR) (Dr. D. Steeger von Keitz, Rüsselsheim, Germany)	48
The treatment of shoulder periarticular calcification by shock waves (Dr. C. de Durante, Napoli, Italy)	49
Shock waves in the treatment of carpal scaphoid non-union (Dr. B. Corrado, Napoli, Italy)	50
Ten years experience with shock wave therapy of pseudarthrosis (Dr. J. Haist, Wörrstadt, Germany)	51
Shock wave treatment of hip necrosis: preliminary results (Dr. S. Russo, Napoli, Italy)	52
Extracorporeal shock wave therapy in the treatment of Dupuytren's and Ledderhose's contraction (Dr. J. Haist, Wörrstadt, Germany)	53

Treatment of shoulder periarticular calcification by medium energy shock waves: 10 cases report (Dr. B. Corrado, Napoli, Italy)	54
The treatment of enthesiopathy such as planter fasciitis, tennis and golfers elbow and similar with extracorporeal shock waves using a modified lithotripter (Dr. G.F. Schmittgen, Buruley, Great Britain)	55
A prospective, blinded, randomised control trial assessing the use of different energy extracorporeal shock wave therapy for calcifying tendonitis (Dr. A. Hearnden, Surrey, Great Britain)	56
The treatment of shoulder periarticular calcifications by shock waves (Dr. C. de Durante, Naples, Italy)	58
A prospective, randomised study comparing shock wave therapy and steroid injection in the treatment of tennis elbow (Dr. M.A. Crowther, Bristol, Great Britain)	59
Chronic achillodynia. Treatment with extracorporeal shock waves (Dr. O. Galasso, Naples, Italy)	60
Chronic achillodynia treatment with ESWT (Dr. B. Zillner, Vienna, Austria)	61
Personal experience with ESWT in musculoskeletal acute lesions during football World Cup 1998 in France (Dr. S. Gigliotti, Naples, Italy)	62
Non-unions treatment and results (Dr. M. Nigrisoli, Bologna, Italy)	63
Axial external fixation plus high energy shock waves in the treatment of unstable leg non-union (Dr. F. Cozzolino, Naples, Italy)	64
Indications and limits of shock waves in the treatment of diaphyseal non-unions (Dr. S. Gigliotti, Naples, Italy)	65
High energy shock waves for pain management in orthopaedics – a two year follow-up in 899 cases (Dr. W. Brunner, Mainburg, Germany)	66

The management of osteonecroses by shock wave treatment (Dr. S. Gigliotti, Naples, Italy)	67
The in vivo cavitation measurement (Dr. S. Russo, Naples, Italy)	68
Extracorporeal Shock Wave Therapy versus Surgical Treatment in Calcifying Tendinitis and Non Calcifying Tendinitis of the Supraspinatus Muscle (Haake M., Rautmann M., Wirth T. 2001)	71

07.2001  
ok/abstracts-literaturverzeichnisse/ortho

43. Jahrestagung der Vereinigung Süddeutscher Orthopäden  
28.04.-01.05.1995, Baden-Baden, Germany

## **ERSTE ERFAHRUNGEN MIT DER EXTRA- KORPORALEN STOSSWELLENTHERAPIE BEI THERAPIERESISTENTER TENDINOSIS CALCAREA**

F. Bernhardt, K. Herken, G. Lenz  
Bremen, Germany

In unserer Studie wurden 12 Patienten mit therapieresistenter Tendinosis calcarea eines Schultergelenks einer 4- bis 5maligen extrakorporalen Stosswellentherapie innerhalb 8 Wochen mit dem Lithotripter STORZ MODULITH SL 10 unterzogen. Dabei wurden je Therapieeinheit 1500 Impulse mit einer mittleren Energiestufe ohne Analgetikabgabe unter fortlaufender sonographischer Kontrolle mit einem 5MHz-Schallkopf verabreicht.

Die Nachuntersuchung erfolgte 2 Wochen nach der letzten Therapieeinheit mit einem eigens entwickelten Score sowie radiologischen und sonographischen Vergleichsaufnahmen.

Dabei fanden sich bei 11 der 12 Patienten sowohl die subjektiven als auch die objektiven Kriterien signifikant verbessert. Die Methode scheint daher erfolgversprechend zu sein. Die Studie wird weiterhin fortgesetzt.

Bei medikamentöser Einflussnahme und dem Einsatz der physikalischen Therapie kann ein Teil der Patienten nicht zufriedenstellend behandelt werden. Die Folge ist zumeist eine zunehmend schmerzhafteste Bewegungseinschränkung der betroffenen Seite bis hin zur sogenannten Frozen shoulder. Adäquat und erfolgreich operativ behandelt werden können nur die Patienten, die ein entsprechend pathologisch-morphologisches Substrat, beispielhaft sei die Rotatorenmanschettenruptur und die ausgedehnte Tendinitis calcarea genannt, aufweisen.

Insgesamt 84 Patienten, die ein umschriebenes Supraspinatussyndrom, ein Bizepssehnsyndrom oder eine kleine Tendinitis calcarea aufweisen und über mehr als 4 Monate erfolglos konservativ behandelt wurden, wurden der extrakorporalen Stosswellentherapie zugeführt. Die Patienten wurden bei einer Totalbehandlungszahl von 193 durchschnittlich 2,3mal behandelt. In aller Regel wurde der Energiebereich von  $0,08 \text{ mJ/mm}^2$  nicht überschritten. Komplikationen traten bei dem minimalinvasiven Therapieverfahren nicht auf. In der Beurteilung des Therapieergebnisses, in die Schmerzhaftigkeit und Beweglichkeit eingingen, wiesen 62 Patienten ein sehr gutes und gutes Resultat auf, lediglich 22 Patienten konnten nicht zufriedenstellend therapiert werden.

Der Einsatz der niedrigenergetischen extrakorporalen Stosswellenanwendung in der Therapie hartnäckiger, umschriebener Schulterschmerzen scheint aufgrund der ersten Resultate eine sinnvolle Ergänzung zu langwierigen und wenig erfolgreichen konservativen Behandlungsmethoden zu sein.

8th International Meeting of the Society for Minimally Invasive Therapy  
18.-20.09.1996, Cernobbio, Italy

## **SHOCK WAVES EMPLOYMENT IN ORTHOPAEDICS AND TRAUMATOLOGY**

L. Felli, S. Bertora, G. Burastero, B. Calandriello, F. Picchetta, L. Derchi\*  
Clinica Ortopedica II dell'Università, Genova, Italy  
\* Istituto di Radiologica dell'Università, Genova, Italy

In the orthopaedic and traumatologic field we find out few pathologies in which surgical treatment is the rule because of the failure of the traditional conservative therapy.

The use of the extracorporeal pressure wave unit, which has been modified for orthopaedic employment, gives us an useful treatment also for pathologies usually treated in the surgical way. The MINILITH SL1 pressure wave therapy unit offered by STORZ MEDICAL is a shock waves generator that, thanks to the ecographic targeting, allows to choose exactly the zone we want to shoot.

At the Orthopaedic department of Genoa University, we have treated patients with joint pathology: shoulder (tendon calcifications, subacromial bursitis, impingement syndrome); knee (tendon and capsular insertional pathologies); foot (Achille's tendon pathology, evolutions of capsular-ligamentous dislocations); elbow (humeri radialis and ulnaris epicondylitis, painful periarticular pathologies).

We have used E1 and E4 with different numbers of shots from 1000 to 1800 for each session. Every treatment has been carried out for 3 weeks at last.

No complications after the treatment were seen and the results have been positive and encouraging in complex.

To evaluate the results we used particular parameters: „remission of pain“ and „improvement of functional activity“ as well as instrumental images.

8th International Meeting of the Society for Minimally Invasive Therapy  
18.-20.09.1996, Mailand, Italy

## **A PILOT INVESTIGATION INTO THE ACTION OF LOW-ENERGY SHOCK WAVES ON IMPAIRED MUSCULAR FUNCTION IN CHILDREN WITH CEREBRAL PALSY AND LOW-BACK PAIN IN ADULTS**

H. Lohse-Busch, M. Kraemer, U. Reime  
Theresienklinik, Bad Krozingen, Germany

Thirty-five children and young people with impaired movement, mostly spastic origin, were treated with 500 pulses of low-energy shock waves directed towards the bellies of the muscles responsible for contractures of the lower limb at a focal pressure of 10 MPa.

Immediately following treatment the range of movement at the hip-joint was increased by an average of 17°, at the knee-joint by 12,3° and the ankle by 7,1°. Each of these increases was statistically significant. The spastic cocontractions, muscular stiffness and myofascial viscoelasticity, as well the dyskinetic and ataxic symptoms, were reduced. An increase in general proprioception brought about an improvement in the body image of the children, and muscle groups in regions of the body remote from the point of impact of the waves showed functional improvement. The treatment is painless, and the improvement lasts for several weeks. This time can be used to establish a better motor pattern.

A second group consisting of 10 adults with chronic low-back pain in the lumbar region of the erector spinae were treated in a similar fashion. On the day following the treatment 8 patients were free of pain, and in 2 the pain was significantly reduced. Schober's lumbar index increased on average by 2,8 cm. These results lasted for at least 10 days and could be used to improve the motor pattern. No undesirable effects were observed.

A few of the patients, both children and adults, showed an euphoric response lasting for about 2 days after treatment.

Kasseler Stosswellensymposium 'Osteologie'  
11.-12.04.1997, Kassel, Germany

## **TREATMENT OF NON UNIONS WITH SHOCK WAVES WITH SPECIAL REFERENCE TO CARPAL SCAPHOID NON UNION**

S. Russo, S. Gigliotti, C. de Durante, R. Canero, B. Corrado  
Università degli Studi di Napoli - Federico II, Napoli, Italy

### **Introduction**

The authors show their experiences in the treatment of the non unions of bone. Since 1992 they have been using shock waves generated by an electromagnetic machine (MODULITH SLX and MINILITH - STORZ) in 125 cases of non union (64 carpal scaphoides) (Tab. 1).

Table 1 - Bone tissue case study

Humerus	3
Falanx	14
Metacarpal	9
Carpal scaphoid	64
Hamate	1
Ulna	4
Radius	2
Femur	13
Tibia	9
Tibia (congenital)	3
Clavicula	1

### **Biological Effects**

The response observed in non union areas is represented by an osteogenetic mechanism and by a vascular response. It is possible to obtain the lamellar fragmentation by using very high power, but this is not mandatory. Lower powers are sufficient to break the hydroxipatite macrocrystals, freeing microcrystals which behave like calcic aggregation nuclei. Thus, an expansion of the osteogenetic response is observed with a similar mechanism to that produced by the macrophages in fresh fractures. The breakage of the macrocrystal may induce bone morphogenetic protein (BMP) release. This is an osteogenetic factor normally present in the bone but not active because it is covered by the hydroxipatite macrocrystal. It is responsible for the mature bone formation through osteogenetic, angiogenetic and fibrillogenetic processes (2).

The vascular response has been studied in both MRI and in three Phase Bone Scyntigraphy (TPBS). The authors observe a first and early vascular response due to the opening of the precapillary sphincters due to the sympaticoplegia induced by the shock wave on the sympaticous fibers. The washout which follows the capillary bed opening determines the removal of the inflammation mediators and the P substance. This explains the transitory pain decrease in the treated patient. Therefore, it is possible to observe a latter and continuous vascular response. According to the authors, this is due to the increased number of capillaries in the treated area. In fact, in nature there is a physiological mechanism of functional adaptation of the tissues to the metabolic activity. When the metabolic request increases constantly in time, the release of a morphogen called Endothelial Stimulating Angiogenetic Factor (ESAF) is observed. This is a low molecular mass peptide which has been studied by varous authors in the last few years (1). The ESAF is an activator of the type 1 collagenasis. As known, the type 1 collagen is the principal element of the basal membrane of the capillaries. The collagenasis activated by the ESAF causes the basal membrane perforation of the capillary. The endothelial cells no longer withheld by the basal membrane migrate in the interstitial space and therefore lead to the formation of new capillary beds. It is possible that a similar mechanism is directly provoked by the shock waves. In 1994, a German author called Marcus Seidl (5), performed an experiment on human fetus ombelical cords which underwent shock waves. He used powers of 0,6 mJ/mm<sup>2</sup> and 2000 shots. He observed the elimination of the endothelial with the exposure of the basal membrane in an area which went form the focal point to a 3 mm distance. Also, the basal membrane was perforated. At distances more than 3 mm from the focal point, an endothelia gap having a diameter of up to 0,5 mm is noticed. As seen in this study, it is possible that shock waves may cause a neoangionesis with a mechanism very similar to that induced by the ESAF.

### **Bone Tissues**

The authors describe the vast personal experience obtained in the last years regarding the treatment of delayed consolidation and non union and more recently, in the field of aseptic necrosis and osteonecrosis.

The therapeutical approach for this treatment must consider a number of parameters which will now be discussed individually.

1. Besides a correct clinical functional exam the pre-treatment study must be completed with X-rays and MRI. These exams give a precise monitoring of the initial stage and important parameters for the treatment indications. They allow the identification of the borderline situations which represent an exclusion criteria or they furnish important information for a prognostic evaluation. They also allow the identifation of the axial devitations and mal-rotations which contra-indicate this treatment. This is true, particularly, for the non unions of articular bones like carpal scaphoid in which the primary objective is to regain articular stability and mobility.

2. The MRI allows evaluation of the presence of ischemic areas or focal osteonecrosis (3). Therefore it is possible to draw a map of the area to be treated by identifying the so called break points. These represent the sites with an altered micro circle which must be treated specifically (4). For bone tissues, it is mandatory to have an X-ray source coinciding with the shock wave source.
3. The precision of the shock wave application represents a fundamental requirement for a positive therapy outcome. The machine is equipped with a three-plane X-ray aiming system, along with a monitorized bed which can carry out micro-movements which allow a correct and comfortable positioning of the patient.
4. Concerning the shock wave power and application number, the authors refer to their experience. As for the small segments like the carpal scaphoid, the powers used vary from 0,2 to 0,6 mJ/mm<sup>2</sup>. Powers from 0,6 to 1,0 mJ/mm<sup>2</sup> are used for larger bones like the femur or tibia.
5. The number of applications depends on the size of the pressure field and the power developed in this area. Therefore, only two treatments can be necessary for small bones which diameters do not exceed those of the pressure field. Instead, larger bones require more applications (Tab. 3).
6. An accurate clinical X-ray and MRI study completes the post-treatment diagnostic phase.

### **Discussion and conclusion**

The number of treated patients is 125; 64 of these have carpal scaphoid non unions (12 distal pole, 29 isthmus, 23 proximal pole). In 14 scaphoids the MRI showed a pre-necrosis. For the carpal scaphoid the 45 days follow up showed a total fusion in 19 patients (Group A), a partial fusion in 29 (Group B) and no fusion in 16 (Group C). The second follow up (45 + 45 days), after another treatment phase, showed 30 patients in Group A, 22 in Group B and 12 in Group C. For the other bones we observed after the treatment phases 54 total fusions (Group A), 4 partial fusions (Group B) and 3 no fusions (Group C); so in conclusion we have had a total of 67,2 % total fusions, 20,8 % partial fusions and 12 % no fusions (Tab. 2).

Table 2 - Non union follow up

Total fusion	84
Partial fusion	26
No fusion	15

Table 3 - Treatment modalities

**Small Bones**

1st treatment phase

MODULITH: 2 applications (24 - 48 h), 4000 shots, Energy level 8/9 or

MINILITH: 4 applicatons (24 h), 4000 shots, Energy level 6

Cast 30 + 20 days (carpal scaphoids)

30 days (other small bones)

Rx

Group A (total fusion): stop treatments

Group B (partial fusion): 2nd treatment phase

Group C (no fusion): 2nd treatment phase

2nd treatment phase

MODULITH

Group B: 2 treatments (24 - 48 h), 4000 shots, Energy level 8/9

Group C: 3 treatments (24 - 48 h), 4000 shots, Energy level 6

MINILITH

Group B and C: 4 treatments, 4000 shots, Energy level 6

Rx after 45 days

Group A: stop treatments

Group B: stop treatment

Group C: failure - stop treatment

**Other Bones (Only MODULITH)**

4 treatments (24 - 48 h), 4000/5000 shots, Energy level 8/9 (without anaesthesia)

Immobilization

1st treatment phase

Rx and MRI after 30 days

Group A: stop treatments

Group B: 2nd treatment phase

Group C: 2nd treatment phase

2nd treatment phase (like 1st)

Rx after 30 days

Group A: stop treatments

Group B: 3rd treatment phase

Group C: 3rd treatment phase

3rd treatment phase (like 1st)

Rx after 45 days

Group A: stop treatments

Group B: sigle applications (aimed on the peripheral areas)

Group C: MRI and new treatment (only in case of improvement of the blood flow)

### **References**

1. Brown M.D.: ESAF in relation to capillary growth. *Int. J. Microc.*, Vol XV, n 3: 111 - 115, 1995
2. Corrado E.M., Russo S., Gigliotti S., de Durante C., Marino D., Cozzolino F., Misani N.: Le onde d'urto ad alta energia nel trattamento delle pseudartrosi. *GIOT IInd, S. Vol XXII, Fas. 2*, 485 - 490, 1996
3. Russo S., Briganti F., Corrado E.M., Gigliotti S., de Durante C.: Treatment of scaphoid non union by lithotripsy. *Vth I.F.S.S.H. Congress - Helsinki*, July 3 - 7, 1995
4. Russo S., Lanza F., Passaretti U., Corrado E.M.: Diagnosis and early treatment of aseptic bone necrosis with high energy shock waves. *IIIrd E.F.S.S.H. Congress, J. Hand Surg.*, Vol 21/B, S. 1, 15, 1996
5. Seidl M., Steinbach P., Worle K., Ofstader F.: Induction of stress fibers and intercellular gaps in human vascular endothelium by shock waves. *Ultrasonics*, 32, 5, 397 - 400, 1994

EFORT - European Federation of National Associations of Orthopaedics  
and Traumatology  
24.-27.04.1997, Barcelona, Spain

## **TENDINITIS CALCAREA OF THE SHOULDER - A PROSPECTIVE CLINICAL AND MR CONTROLLED STUDY OF 42 PATIENTS TREATED BY EXTRACORPOREAL SHOCK WAVES**

M. Maier, B.M. Delsmann, H.J. Refior  
Klinikum Grosshadern, München, Germany

### **Purpose of the study**

It is reported about satisfactory clinical results by using extracorporeal shock waves (ESWL) in the treatment of tendinitis calcarea, it is not often informed on morphologic findings in the treated areas of the shoulder combined with an application of a clinical score.

### **Material and methods**

From January to July 1996, 42 patients with clinically and radiologically proven tendinitis calcarea of the shoulder were treated by ESWL and registered prospectively. There were 27 (64,3 %) female and 15 (35,7 %) male persons aged from 29 - 72 years. All were treated non operative in vain because of the tendinitis calcarea for at least 6 months.

ESWL was performed in three to six individual sessions using a MINILITH SL1. In all cases a low to moderate energy level of ESWL was used. Before the first session and within 12 hours after the first session the MR was performed natively and with Gd-DTPA i.v. The Constant-Murley Shoulderscore was collected before all sessions.

### **Results**

In 12 patients (28,5 %) a contrast medium enrichment was seen in the MR around the calcareous accumulation after the first session. There were three cases (7,1 %) where the calcareous accumulation had changed its contour, one bone oedema was seen. Considering the Constant-Murley Score before the first ESWL session, an average of 38 points was calculated, after the first session 49 points, after the second one 64 points, after the third one 73 points. Especially the pain was estimated to diminish within two sessions. There were no neurological complications, in six patients (14,2 %) a haematoma was seen.

**Conclusions**

The ESWT is appropriate for the therapy of long-time tendinitis calcarea. Corresponding to the results of the post session MR evaluation, there is no reliable sign to explain the effect of the ESWT on the calcareous accumulation. There were no pathological findings at the bones after performing the method. According to the number of sessions an improvement of the clinical score was seen.

45. Jahrestagung der Vereinigung Süddeutscher Orthopäden e.V.  
01.-04.05.1997 in Baden-Baden, Germany

## **KERNSPINTOMOGRAPHISCHE VERÄNDERUNGEN DER SCHULTERREGION NACH STOSSWELLENTHERAPIE DER TENDINITIS CALCAREA**

M. Maier, P. Schnarkowski, M. Pfahler, H.J. Refior  
Klinikum Grosshadern, München, Germany

Die Anwendung extrakorporaler Stosswellen zur Therapie der Tendinitis calcarea ist heute in der Diskussion. Ziel der vorliegenden Arbeit ist die Beschreibung und Diskussion prospektiv erhobener, kernspintomographisch nachweisbarer morphologischer Veränderungen der Schulterregion nach Stosswellentherapie (ESWT) unter der Indikation der Tendinitis calcarea.

### **Material und Methodik**

Von Januar bis September 1996 wurde bei 24 Patienten mit über sechs Monate therapieresistenter Tendinitis calcarea eine ESWT durchgeführt. Behandelt wurden 14 weibliche (58 %) und 10 männliche (42 %) Patienten. Das mittlere Lebensalter betrug 51,3 Jahre. Pro Patient wurden drei Applikationen (1/Woche) mit 2000 Impulsen/Applikation durchgeführt. Die Intensität der Impulse wurde dem nieder-energetischen Stosswellenbereich zugeordnet gewählt. Alle Patienten wurden vor der ersten und nach der dritten ESWT-Behandlung MR-tomographisch (T1, T2, Gradientenecho, T1 mit Kontrastmittel) und nativ-radiologisch untersucht.

### **Ergebnisse**

In den T1 gewichteten Aufnahmen mit Kontrastmittel vor ESWT zeigten 17 Patienten (70,8 %) ein positives, 7 (29,2 %) ein negatives Kontrastmittelverhalten. Nach ESWT zeigten 13 Patienten (54,2 %) ein positives, (45,8 %) ein negatives Kontrastmittelverhalten. In den T2 gewichteten Aufnahmen fand sich vor ESWT eine komplette Rotatorenmanschettenruptur. Nach ESWT war in dieser Sequenz keine Blutung, Ödem oder Verletzung im behandelten Gebiet nachweisbar. In der Gradientenechosequenz konnten vor ESWT bei 22 Patienten (91,7 %) die Kalkdepots dargestellt werden, bei fünf Patienten (20,8 %) zeigte sich nach ESWT hierin eine Veränderung. 19 mal (79,2 %) fand sich vor ESWT das Kalkdepot im Bereich der Sehne des M. supraspinatus.

### **Diskussion**

Es konnten für den niederenergetischen Therapiebereich bei Tendinitis calcarea keine morphologisch fassbaren, ungewünschten Schäden des Knochen- und Weich-gewebes im MRT dargestellt werden. Das Kontrastmittelverhalten in den T1 Sequenzen hatte keinen Einfluss auf das klinische Ergebnis. Die in der Gradienten-echosequenz dargestellten Kalkdepotveränderungen hatten keinen Einfluss auf das klinische Ergebnis. Zur Beurteilung des Kalkdepots ist die Gradientenechosequenz geeignet, jedoch erbringen nativ-radiologische Aufnahmen ähnliche Ergebnisse.

45. Jahrestagung der Vereinigung Süddeutscher Orthopäden e.V.  
01.-04.05.1997 in Baden-Baden, Germany

## **PILOTUNTERSUCHUNG ZUR WIRKUNG VON NICHTFOKUSSIERTEN, EXTRAKORPORALEN STOSSWELLEN AUF MUSKELFUNKTIONSTÖRUNGEN BEI KINDERN MIT INFANTILER ZEREBRALPARESE**

H. Lohse-Busch, M. Kraemer, U. Reime  
Theresienklinik, Bad Krozingen, Germany

### **Untersuchung I**

Bei 35 Kindern und Jugendlichen mit spastischen Bewegungsstörungen wurden die Muskelbäuche der Beugekontrakturen verursachenden Muskeln der unteren Extremitäten mit jeweils 500 Impulsen nichtfokussierter (Fokus 3 cm innerhalb der Therapiequelle), niederenergetischer, extrakorporaler Stosswellen (ESW) des MINILITH SL1 (Fa. STORZ MEDICAL AG) Stufe 1 und 2 behandelt.

Der Bewegungsumfang der Hüftgelenke nahm durchschnittlich um 17 Grad, der Kniegelenke um 12,3 Grad und der Sprunggelenke um 7,1 Grad statistisch signifikant zu. Die biomechanischen Verbesserungen halten mehrere Wochen an. Die Zeit kann zur Anbahnung verbesserter Bewegungsmuster genutzt werden. Die Untersuchung war durch eine Ethikkommission genehmigt.

Im Rahmen einer kontrollierten Untersuchung wurden 7 Kinder, die während 2 Wochen mit ESW behandelt worden waren, vor und nach der Behandlung einer neuro-psychologischen Untersuchung mit dem K-ABC-Test und TÜKI-Test unterzogen. Die intellektuellen Fertigkeiten verbesserten sich durchschnittlich um 15,1 T-Werte, die kulturellen Fertigkeiten um 3 T-Werte und die sensomotorische Integrationsfähigkeit um 18,5 T-Werte. Die kleine Zahl der untersuchten Kinder lässt nur die Diskussion von Tendenzen zu.

### **Untersuchung II:**

20 erwachsene Versuchspersonen waren gleichartig mit ESW bis Stufe 4 behandelt worden. CPK, CK-MB, LDH, HBDH, aP und GPT im Serum veränderten sich nicht.

### **Zusammenfassung**

Niederenergetische, nicht fokussierte, dispergierende ESW sind in der Lage, muskuläre Rigidität und spastische Hypertonie bei ICP-Kindern zu mildern. Eine erleichterte Biomechanik hat ein erweiterte Sensomotorik zur Folge. Es zeigen sich Tendenzen, dass folgerichtig auch kognitive und feinmotorische Fähigkeiten verbessert werden.

Bei fortbestehender Grundkrankheit kann das Ergebnis nicht dauerhaft sein. Wiederholungsbehandlungen haben sich bewährt. Zelluläre Schädigungen sind ausgeschlossen worden. Auch über einen Zeitraum von mehr als 12 Monaten wurden keine unerwünschten Nebenwirkungen beobachtet.

Kontrollierte Untersuchungen bei ICP-Kindern unter Ganglaborbedingungen und zu orthopädischen Schmerzbildern wurden begonnen. Über diese Ergebnisse wird berichtet werden.

46. Jahrestagung der Norddeutschen Orthopädenvereinigung e.V.  
12. - 14.06.1997 in Bremen, Germany

## **BEHANDLUNGSERGEBNISSE DER MITTELENERGETISCHEN STOSSWELLENTHERAPIE BEI TENDINOSIS CALCAREA**

T. Wallny, B. Düsseldorf, H. Klippert, M. Buhr, O. Schmitt  
Bonn, Germany

### **Fragestellung**

Evaluation der ESWT bei Tendinosis calcarea.

### **Methodik**

Von 1995 bis 1996 wurden 88 Patienten mit einer konservativ therapieresistenten Tendinosis calcarea mit der ESWT behandelt. Dabei wurden 1500 Impulse der Energieflussdichte  $0,23 \text{ mJ/mm}^2$  in durchschnittlich 5,2 Sitzungen appliziert.

### **Ergebnisse**

Von den 88 Patienten (Durchschnittsalter 52 Jahre) konnten 80 (90,9 %) nachuntersucht werden. Im Constant-Score war ein Anstieg von 53 auf 80 Punkte zu verzeichnen. In 37,5 % (n=30) gelang eine Auflösung des Kalkdepots, in 50 % (n=40) eine Verkleinerung oder Desintegration, in 20 Fällen (25 %) war keine Änderung des Kalkdepots zu erzielen, obwohl 30 % dieser Patienten schmerzgebessert waren. Subjektiv gaben 86 % der Patienten eine Besserung bzw. Beschwerdefreiheit an.

### **Fazit**

Unsere Ergebnisse unterstreichen die Wertigkeit der ESWT als nichtinvasive Operationsalternative. Die hohe Anwendungszahl pro Patient zeigt, dass Erfolge erst nach 4 und mehr Behandlungen eintreten können.

46. Jahrestagung der Norddeutschen Orthopädenvereinigung e.V.  
12. - 14.06.1997 in Bremen, Germany

## **DIE NIEDRIGENERGETISCHE ESWT IN DER BEHANDLUNG DER EPICONDYLITIS HUMERI RADIALIS**

T. Wallny, B. Düsseldorf, H. Klippert, M. Buhr, O. Schmitt  
Bonn, Germany

### **Ziel**

Überprüfung der Wirksamkeit der anästhesiefreien ESWT.

### **Methode**

Von 1995 bis 1996 wurden 40 Patienten wegen einer konservativ therapieresistenten Epicondylitis humeri radialis mit der ESWT behandelt. Dabei wurden 1500 Impulse einer mittleren Energieflussdichte von 0,17 mJ/mm<sup>2</sup> in durchschnittlich 5,1 Sitzungen appliziert.

Die Therapie wurde unter sonographischer Kontrolle und Selbsteinstellung des Patienten auf den Hauptschmerzpunkt durchgeführt.

### **Ergebnisse**

Beschwerdefrei waren 60 % (n=24), beschwerdegebessert 15 % (n=6), in den restlichen 25 % konnten keine längeranhaltenden positiven Therapieeffekte vermerkt werden. In drei Fällen zeigte sich ein zeitlich begrenzter Therapieerfolg von drei Monaten.

Auf der visuellen Analogskala zeigte sich ein Rückgang der Werte von durchschnittlich 7,6 auf 3,2 cm. Der chair-Test zeigte sich vor Behandlung in 80 %, danach in 30 % positiv. Der positive Mittelfingerstrecktest veränderte sich von 65 auf 20 %. Belastungsschmerzen nach der Behandlung wurden von 30 % der Patienten angegeben.

### **Fazit**

Bei der Epicondylitis humeri radialis lassen sich mit niedrigen Energieflussdichten Therapieerfolge erzielen, so dass die ESWT als Operationsalternative anzusehen ist, wenn herkömmliche Behandlungsverfahren ausgeschöpft sind.

46. Jahrestagung der Norddeutschen Orthopädenvereinigung e.V.  
12. - 14.06.1997 in Bremen, Germany

## **NIEDERENERGETISCHE ESWT BEI CHRONISCHEM TENNISELLENBOGEN - SIND DIE ERGEBNISSE GERÄTEABHÄNGIG ?**

O. Krischek, M. Stratmann, J. Vogel, J.-D. Rompe  
Orthopädische Universitätsklinik, Mainz, Germany

### **Ziel der Arbeit**

Die Absicht dieser Studie war, den Unterschied der Ergebnisse niederenergetischer Stosswellentherapie bei chronischer Epicondylitis humeri radialis mit zwei verschiedenen Stosswellengeräten herauszufinden.

### **Methodik**

Von Januar 1996 bis Juli 1996 behandelten wir prospektiv randomisiert 60 Patienten, die mindestens 6 Monate über charakteristische Ellenbogenbeschwerden klagten und erfolglos konservativ behandelt worden waren, in zwei Gruppen mit niederenergetischer Stosswellentherapie. Die erste Gruppe erhielt 3 x 500 Impulse der Stärke 0,08 mJ/mm<sup>2</sup> mit dem Osteostar-Experimentalgerät von Siemens (Siemens AG, Erlangen), und die zweite Gruppe erhielt 3 x 500 Impulse der Stärke 0,06 mJ/mm<sup>2</sup> mit dem MINILITH SL1 (STORZ MEDICAL AG, Kreuzlingen, Schweiz). Die Patienten wurden 3, 6 und 12 Wochen nach der Stosswellenbehandlung nachuntersucht. Die Ergebnisse der Behandlung wurden beurteilt durch subjektive Angaben der Patienten über die prozentuale Besserung der Beschwerden und eine visuelle Analogskala von 0 bis 10 betreffend den Ruheschmerz, Nachtschmerz, Druckschmerz, Thomson-Test, Mittelfingerstrecktest und Stuhl-Hebe-Test (chair-Test). Zusätzlich erfolgte eine Messung der schmerzfremen Faustschlusskraft mit einem Dynamometer.

### **Ergebnisse**

Die mittlere subjektive Besserung der Schmerzen nach 12 Wochen wurde in Gruppe I mit 44 %, in Gruppe II mit 53 % angegeben. Die Faustschlussstärke stieg in Gruppe I von initial 19,9 kg auf 33,5 kg nach 12 Wochen und in Gruppe II von 25,2 kg auf 29,5 kg. Im Ellenbogen-Score von Verhaar et al. (1993) erreichten wir ein sehr gutes Ergebnis, das heisst eine Schmerzfremheit, bei 5 Patienten der Gruppe I und bei 6 Patienten der Gruppe II, gute Ergebnisse 10 mal in Gruppe I und 13 mal in Gruppe II. Mässige und schlechte Ergebnisse erhielten wir bei 15 Patienten der Gruppe I und bei 11 Patienten der Gruppe II. Die Ergebnisse der visuellen Analogskala siehe in Tab. 1.

Tab. 1

	vor Therapie		12 Wochen nach Behandl.	
	Gruppe I	Gruppe II	Gruppe I	Gruppe II
VAS (0 bis 10)				
Druckschmerz	5.8	5.9	4.4	3.9
Thomson-Test	5.6	5.7	3.6	2.3
Mittelfingerstrecktest	3.3	4.4	1.1	1.8
chair-Test	5.4	5.1	3.1	2.0

### **Schlussfolgerung**

Neben dem Einfluss der Impulsanzahl und -energie der applizierten Stosswellen scheint eine Abhängigkeit der Ergebnisse von dem verwendeten Stosswellengerät zu bestehen. In unserer Studie ergaben sich tendenziell bessere Ergebnisse bei der Verwendung des MINILITH SL1 in der niederenergetischen Stosswellentherapie des chronischen Tennisellenbogens.

46. Jahrestagung der Norddeutschen Orthopädenvereinigung e.V.  
12. - 14.06.1997 in Bremen, Germany

## **ERSTE ERGEBNISSE ZUM EINSATZ DER EXTRAKORPORALEN STOSSWELLENTHERAPIE IN DER SPORTORTHOPÄDIE**

H. Lohrer, J. Schöll, W. Alt, M. Hirschmann  
Sportmedizinisches Institut, Frankfurt a.M., Germany

### **Fragestellung bzw. Ziel der Arbeit**

Im eigenen sportorthopädischen Krankheitsgut werden 22 % Insertionsendopathien und 3,2 % Stressfrakturen diagnostiziert. Genau diese Krankheitsbilder zeigen im Sport einen in der Regel eigengesetzlichen Verlauf. Die therapeutischen Interventionen waren bisher limitiert und die Ergebnisse auch operativer Interventionen sind nicht durchgängig gut.

Der Wert der extrakorporalen Stosswellentherapie als nichtinvasive Behandlungsform bei derartigen sportspezifischen Krankheitsbildern könnte theoretisch einen wesentlichen Fortschritt im Behandlungsergebnis der chronifizierenden Sehnen-erkrankungen im Sport bringen. Der Wert der Methode für diesen Indikationsbereich soll anhand erster Ergebnisse dargestellt werden.

### **Methodik**

90 Patienten, die wegen sportassoziierter Insertionsendopathien und wegen chronifizierender Stressfrakturen mit der extrakorporalen Stosswellentherapie behandelt wurden, wurden retrospektiv mit einem Fragebogen nachuntersucht.

Die Rücklaufquote der Fragebögen betrug 60 %. Bei einer Nachuntersuchungszeit von durchschnittlich 6 Monaten waren insgesamt 45 % der behandelten Patienten beschwerdefrei geworden und geblieben. In 30 % der Fälle stellte sich eine teilweise Verbesserung des Krankheitsbildes ein. 25 % der Patienten gaben an, ein unverändertes Schmerzbild zu verspüren. Eine Verschlimmerung war in einem Fall eingetreten. Auf einer visuellen Analogskala zeigte sich eine Schmerzreduktion von durchschnittlich 29 %.

Bezogen auf die Dauer der Anamnese zeigte sich, dass bei kürzerer Beschwerdedauer (unter 6 Monaten) eine hohe Erfolgsquote (64 % schmerzfrei) nachweisbar war, während bei einer längeren schmerzhaften Vorgeschichte (über 6 Monate) lediglich 34 % der ESWT-Behandelten schmerzfrei wurden. Die Versagerquote lag in den beiden Gruppen bei 21 bzw. 28 %.

Bezogen auf die aus der Literatur bekannten Standardindikationen konnten wir bei den Epikondylopathien am Ellenbogen 30 %, bei der Fasciitis plantaris und Fersenspornleiden 67 % und bei Schulteraffektionen in 50 % Schmerzfreiheit erzielen.

Bei der Prüfung neuer sportspezifischer Behandlungsansätze fand sich für das chronifizierende Patellaspitzen- und Tibiakantensyndrom in 33 %, bei den Stressfrakturen in 67 % eine vollständige Schmerzfreiheit nach der extrakorporalen Stosswellentherapie.

### **Schlussfolgerung**

Unter dem Aspekt, dass die sportspezifischen Insertionsendopathien in der Regel einen ausserordentlich chronifizierenden Verlauf nehmen, der häufig nur schwer beeinflussbar ist, muss die extrakorporale Stosswellentherapie als relevante Behandlungsalternative vor allem für die hier geprüften chronifizierenden Schmerzsyndrome angesehen werden, besonders, wenn die weiteren konservativen Vorbehandlungsmodalitäten bereits ohne Erfolg ausgeschöpft wurden.

Auch im absoluten Spitzensport und im unmittelbaren Wettkampfumfeld, z.B. bei den Olympischen Spielen 1996 in Atlanta, konnte eine ausserordentlich günstige Beeinflussung vor allem frischer, knochenaher Weichteilschmerzsyndrome mit diesem neuen Behandlungskonzept nachgewiesen werden.

46. Jahrestagung der Norddeutschen Orthopädenvereinigung e.V.  
12. - 14.06.1997 in Bremen, Germany

## **THERAPIERESISTENTE ANSATZTENDINOSEN - INDIKATION ZUR ESWT ODER ZUR OPERATION ?**

C. von Hasselbach  
Arthroskopische Tagesklinik, Essen, Germany

1995 wurde an 63 Patienten wegen therapieresistenter Epikondylitis eine Denervierungsoperation nach Wilhelm durchgeführt und an 56 Patienten eine arthroskopische subakromiale Dekompression wegen Supraspinatus-, Bizepssehnsyndrom bzw. Tendinosis calcarea subacromialis. Seit Januar 1996 wurden diese Indikationen fast ausschliesslich mit extrakorporaler Stosswellentherapie behandelt, 82 Patienten wegen Epikondylitis, 62 an der Schulter, 12 wegen Fasziiitis plantaris und 44 mit anderen Indikationen. Insgesamt wurden bis August 1996 199 Patienten mit ESWT behandelt. 6 Monate nach Abschluss der Behandlung wurden 192 Patienten (96,5 %) nachuntersucht. In dieser Untersuchung sollte geklärt werden, ob mit ESWT im Kurzzeitverlauf vergleichbare Resultate erzielt werden können wie beim operativen Vorgehen.

Als Therapiestandards galten für alle Patienten:

keine Anästhesie oder Analgetika, keine begleitende Medikation, keine Arbeitsunfähigkeit. Die Evaluation erfolgte anhand eines Follow-up-Bogens unter Verwendung einer visuellen Analogskala bei jeder Behandlungssitzung und nach Ablauf eines halben Jahres, Lokalisation und Intensität des maximalen Schmerzpunktes sowie Funktionstest, wie Mittelfingerstrecktest, chair-Test, etc.

Bei der Epicondylitis humeri radialis bestand eine durchschnittliche Anamnese-dauer von 2,5 Jaren mit drei Vorbehandlern. In 2,4 Sitzungen wurde eine mittlere Energieflussdichte von  $0,05 \text{ mJ/mm}^2$  appliziert. 2 Patienten brachen die Behandlung ab. Unter Einschluss dieser Therapieversager wurde nach der Analog-skala der Therapieerfolg im Schnitt mit 87,3 % bewertet. Der volle Wirkungseintritt war 3,9 Wochen nach Behandlungsbeginn erreicht.

Durchschnittliche Anamnesedauer an der Schulter 2,6 Jahre bei 2,7 Vorbehandlern. In 3,4 Sitzungen wurden im Mittel  $0,07 \text{ mJ/mm}^2$  appliziert. Unter Einschluss von 3 Therapieversagern wurde der Behandlungserfolg bei 82,3 % eingeschätzt. Voller Wirkungseintritt nach 5,3 Wochen.

Sehr gute Ergebnisse konnten ebenfalls bei der Achillodynie erzielt werden, während bei der Fasziiitis plantaris das Ergebnis schlecht war. Anamnesezeit durchschnittlich 1,5 Jahre bei 2 Vorbehandlern. Durchschnittliche Anzahl der Sitzungen 3,7 bei einer Energieflussdichte von  $0,06 \text{ mJ/mm}^2$ . Bei insgesamt 12 Patienten fanden sich 7 Therapieversager, so dass der Behandlungserfolg bei 33 % eingeschätzt wurde, der volle Wirkungseintritt nach 3,5 Wochen.

Mit Einschränkung der kurzen Follow-up-Zeit von 6 Monaten zeigt sich die ESWT am Ellenbogen und an der Schulter den operativen Verfahren überlegen. Die hohe Versagerrate bei der Fasziiitis plantaris ist eventuell auf zu geringe Energieflussdichten zurückzuführen. Zu diskutieren ist auch eine vorübergehende Entlastung des behandelten Fusses. Die Latenz von 4 bis 6 Wochen bis zum vollen Wirkungseintritt nach ESWT deutet darauf hin, dass der Wirkungsmechanismus in einer lokalen Gewebedesintegration zu suchen ist mit nachfolgender autonomer Heilung.

Gemeinsamer Jahreskongress der Schweiz. Gesellschaft für Orthopädie (SGO) und der Belg. Gesellschaft für orth. und traum. Chirurgie (SOBCOT)

17. – 20.09.1997 in Montreux, Switzerland

## **DIE EXTRAKORPORALE STOSSWELLENTHERAPIE (ESWT) AM BEWEGUNGSAPPARAT: ERSTE ERFAHRUNGEN / RESULTATE**

B. Dubs

Institut für Sonographie, Spital Bethanien, Zürich, Switzerland

Seit Herbst 1995 führen wir die ESWT am Bewegungsapparat durch. Die ersten 50 Patienten wurden ein Jahr nach der ESWT ausgewertet. Das Kollektiv setzte sich zusammen aus 43 Patienten mit Tendinosis calcarea, 4 mit Fasciitis plantaris (wovon 3 mit Fersensporn), 2 mit Epicondylitis humeri radialis sowie 1 mit verkalkter Bursitis trochanterica.

Einschlusskriterien waren: Therapieresistenz von mindestens drei Monaten, erfolglose Applikation von mindestens einer Serie Physiotherapie und einer Mischinfiltration. Ausschlusskriterien waren eine signifikante Rotatorenmanschettenläsion, eine lokale Infektion oder eine Gerinnungsstörung. Die Therapie bestand aus 2 Sitzungen, welche ambulant im Abstand von 1 – 2 Wochen durchgeführt wurden. Nach Lokalanästhesie wurden jeweils 2000 Stosswellen in mittlere-energetischer Technik auf das Kalkdepot oder an die Schmerzstelle appliziert. Die Behandlungen wurden meist als schmerzhaft, aber erträglich empfunden. Lokalreaktionen in Form von leichten Rötungen oder kleinen Suffusionen waren die Regel, klangen aber stets komplikationslos ab. In diesem Kollektiv erfolgte noch keine Selektion nach Art und Lage der Verkalkungen.

Wir erreichten folgenden Resultate:

<u>Lokalisation</u>	<u>beschwerdefrei</u>	<u>deutlich besser</u>	<u>Versager</u>
Tendinosis calcarea	25 (58.1%)	11 (25.6%)	7 (16.3%)
Fasciitis plantaris	1	3	0
Epicondylitis humeri	1	1	0
Bursitis trochanterica	1		

Die meisten Veränderungen geschahen im Zeitraum des ersten Monats nach der ESWT, nach dem dritten Monat konnten kaum noch weitere Verbesserungen festgestellt werden. In zwei Fällen wurde 6 Monate nach der Erstbehandlung noch eine dritte Behandlung durchgeführt, die einmal vollen, einmal keinen Erfolg erbrachte.

In zwei Fällen wurde nach vorübergehender Beschwerdefreiheit eine erneute leichte Verschlechterung festgestellt. Interessant war die Tatsache, dass bei der Tendinosis calcarea auch Besserung oder Beschwerdefreiheit erreicht werden konnte, ohne dass der radiologische Befund der Verkalkung signifikant abnahm. Es muss also angenommen werden, dass der Behandlungserfolg bei der Tendinosis calcarea nicht nur auf der Desintegration des Kalkdepots beruht. Insgesamt ist die ESWT am Bewegungsapparat eine interessante Alternative, deren Indikation vor einem allfälligen operativen Eingriff geprüft werden sollte.

35. Deutscher Sportärztekongress  
25. – 27.09.1997 in Tübingen, Germany

## **BEHANDLUNGSERGEBNISSE DER EXTRA- KORPORALEN STOSSWELLENTHERAPIE (ESWT) IN DER SPORTORTHOPÄDIE**

J. Schöll, H. Lohrer, M. Hirschmann  
Sportmedizinisches Institut, Frankfurt, Germany

### **Fragestellung**

Wert der extrakorporalen Stosswellentherapie bei den Insertionstendopathien in Sport.

### **Methodik**

Es wurden durchschnittlich 3,8 Behandlungen pro Patient durchgeführt mit 1500 Applikationen pro Behandlung und einer Energiedichte von 0,03 bis 0,25 mJ/mm<sup>2</sup>. 87 Patienten wurden retrospektiv mit Hilfe eines Fragebogens nachuntersucht.

### **Ergebnisse**

Bei einer Nachbeobachtungszeit von durchschnittlich 6 Monaten war das Therapieergebnis bei 38% der Patienten gut, bei 37% befriedigend und bei 25% der Patienten unbefriedigend. Bezogen auf die Dauer der Anamnese zeigte sich, dass bei kürzerer Beschwerdedauer (unter 6 Monaten) eine höhere Erfolgsquote (55% schmerzfrei) nachweisbar war, während bei einer längeren Anamnesedauer (über 6 Monate) lediglich nur 30% der ESWT-Behandelten schmerzfrei wurden. Die Quote der Therapieversager lag in beiden Gruppen bei 14% bzw. 30%: Auch im unmittelbaren Wettkampfumfeld (Atlanta 1996) wurden bei frischen Weichteilschmerzsyndromen gute Ergebnisse erzielt.

### **Schlussfolgerung**

Die extrakorporale Stosswellentherapie kann als relevante Behandlungsalternative vor allem für die hier geprüften chronifizierenden Schmerzsyndrome angesehen werden. Die Behandlung mit der Stosswelle sollte noch in den ersten 6 Monaten zum Einsatz kommen.

61. Jahrestagung der Dt. Gesellschaft für Unfallchirurgie e.V.  
19. – 22.11.1997, Berlin, Germany

## **THERAPIERESISTENTE ANSATZTENDINOSEN. INDIKATION ZUR ESW THERAPIE ODER ZUR OP?**

Ch. von Hasselbach  
Arthroskopische Tagesklinik, Essen, Germany

### **Zielsetzung**

1995 wurde an 63 Patienten wegen therapieresistenter Epicondylitis eine Denervierungsoperation nach Wilhelm durchgeführt und an 56 Patienten eine arthroskopische subacromiale Dekompression wegen Supraspinatus-, Bizepssehnsyndrom bzw. Tendinosis calcarea subacromialis. Seit Januar 1996 wurden diese Indikationen fast ausschliesslich mit Extrakorporaler Stosswellentherapie behandelt, 82 Patienten wegen Epicondylitis, 62 an der Schulter, 12 wegen Faszitis plantaris und 44 mit anderen Indikationen. Insgesamt wurden bis August 1996 199 Patienten mit ESWT behandelt. 6 Monate nach Abschluss der Behandlung wurden 192 Patienten (96,5%) nachuntersucht. In dieser Untersuchung sollte geklärt werden, ob mit ESWT im Kurzzeitverlauf vergleichbare Resultate erzielt werden können wie beim operativen Vorgehen.

### **Methode und Ergebnisse**

Als Therapiestandards galten für alle Patienten: Keine Anästhesie oder Analgetika, keine begleitende Medikation, keine Arbeitsunfähigkeit. Die Evaluation erfolgte anhand eines Follow up Bogens unter Verwendung einer visuellen Analogskala bei jeder Behandlungssitzung und nach Ablauf eines halben Jahres, Lokalisation und Intensität des maximalen Schmerzpunktes sowie Funktionstests, wie Mittelfingerstrecktest, Chairtest, etc.

Bei der Epicondylitis humeri radialis bestand eine durchschnittliche Anamnesedauer von 2,5 Jahren mit 3 Vorbehandlern. In 2,4 Sitzungen wurde eine mittlere Energieflussdichte von 0,05 mJ/mm<sup>2</sup> appliziert. 2 Patienten brachen die Behandlung ab. Unter Einschluss dieser Therapieversager wurde nach der Analogskala der Therapieerfolg im Schnitt mit 87,3% bewertet. Der volle Wirkungseintritt war 3,9 Wochen nach Behandlungsbeginn erreicht. Durchschnittliche Anamnesezeit an der Schulter 2,6 Jahre bei 2,7 Vorbehandlern. In 3,4 Sitzungen wurden im Mittel 0,07 mJ/mm<sup>2</sup> appliziert. Unter Einschluss von 3 Therapieversagern wurde der Behandlungserfolg bei 82,3% eingeschätzt. Voller Wirkungseintritt nach 5,3 Wochen. Sehr gute Ergebnisse konnten ebenfalls bei der Achillodynie erzielt werden, während bei der Faszitis plantaris das Ergebnis schlecht war. Anamnesezeit durchschnittlich 1,5 Jahre bei 2 Vorbehandlern.

Durchschnittliche Anzahl der Sitzungen 3,7 bei einer Energieflussdichte von 0,06 mJ/mm<sup>2</sup>. Bei insgesamt 12 Patienten fanden sich 7 Therapieversager, so dass der Behandlungserfolg bei 33 % eingeschätzt wurde, der volle Wirkungseintritt nach 3,5 Wochen.

### **Schlussfolgerung**

Mit Einschränkung der kurzen Follow up Zeit von 6 Monaten zeigt sich die ESWT am Ellenbogen und an der Schulter den operativen Verfahren überlegen. Die hohe Versagerrate bei der Fasziiitis plantaris ist auf zu geringe Energieflussdichte zurückzuführen. Zu diskutieren ist auch eine vorübergehende Entlastung des behandelten Fusses. Die Latenz von 4 bis 6 Wochen bis zum vollen Wirkungseintritt nach ESWT deutet darauf hin, dass der Wirkungsmechanismus in einer lokalen Gewebedesintegration zu suchen ist mit nachfolgender autonomer Heilung.

4. Jahreskongress der Deutschen Assoziation für Orthopädische  
Fusschirurgie e.V. (D.A.F.)  
13.-14.03.1998, Stuttgart, Germany

## **EXTRAKORPORALE STOSSWELLENTHERAPIE BEI HEEL PAIN**

F.O. Steeb  
Orthopädische Praxis, Stuttgart, Germany

Von September 1995 bis Oktober 1997 wurden insgesamt 88 konservativ  
austherapierte Patienten mit plantarem Fersensporn und Plantarfasciitis mit einem  
Lithotripter der Firma STORZ (MINILITH SL1) therapiert. Obligatorisch bestand  
die Mindestvorbehandlung in einer Einlagenversorgung, orale NSAR und/oder  
orale Steroidinjektionen sowie physikalischer Therapie.

Bewertet wurde die Schmerzintensität vor und nach der Behandlung sowie nach  
3, 6 und 12 Monaten. Die Einstufung der Schmerzintensität wurde mittels der  
visuellen Analogskala (0 – 10) vorgenommen.

Die durchschnittliche Sitzungszahl lag bei 3,5 Sitzungen. 70 % der Behandlungen  
wurden ohne Lokalanästhesie durchgeführt.

Nach Abschluss der Behandlung waren 18 % völlig beschwerdefrei, 42 % gaben  
eine deutliche Besserung ( $\geq 5$  auf der visuellen Analogskala) an. Nach 3 Monaten  
waren 24 % völlig beschwerdefrei, 40 % gaben eine deutliche Besserung an. Nach  
6 Monaten waren 30 % völlig beschwerdefrei, 45 % gaben eine deutliche  
Besserung an.

Diese Ergebnisse waren nach 1 Jahr unverändert.

Gravierende Nebenwirkungen konnten nicht festgestellt werden.

Zusammenfassend lässt sich festhalten, dass die ESWT beim Heel Pain eine  
Alternativbehandlung mit hoher Erfolgsquote trotz negativ selektiertem  
Patientengut darstellt.

3. Kasseler Stosswellensymposium  
03.-04.04.1998, Kassel, Germany

## **UNTERSUCHUNG ZUM WIRKMECHANISMUS DER NIEDERENERGETISCHEN EXTRAKORPORALEN STOSSWELLENTHERAPIE (ESWT) IM MODELL DER RATTE**

M. Haake, A. Thon, M. Bette, E. Weihe  
Orthopädische Universitätsklinik, Marburg, Germany

Aufgrund der klinischen Beobachtungen, dass die niederenergetische ESWT analgetische Effekte hervorruft, werden verschiedene neuronale Wirkmechanismen der ESWT in der Literatur diskutiert. Der Nachweis des tatsächlichen Mechanismus steht bislang noch aus. Die Auswirkungen der niederenergetischen ESWT auf Anzahl und Qualität der C-Fasern, auf die Änderung der Transmitterexpression im Rückenmark und lokal im Beschussfeld, wurde untersucht. Hierzu wurde der immunzytochemische Nachweis verschiedener Neurotransmitter (z.B. CGRP, SP, NPY, TH) und endogenen Opioiden im Rückenmark durchgeführt. In Ratten, deren rechte Hinterpfote mit verschiedenen Dosen behandelt wurden, zeigte sich keine Veränderung der Transmitter- und Opioidexpression im Rückenmark. Ebenso konnte keine Veränderung der Transmitterexpression in der behandelten Pfote gemessen werden. Eine Auswirkung auf die lokale Gefäßregulation erscheint möglich. Lichtmikroskopisch erkennbare Neurodestruktionen im Therapiegebiet sind ausgeschlossen worden.

Der mögliche Effekt der niederenergetischen ESWT auf neuronales sprouting (Auswachsen von Nervenfasern), nachzuweisen durch GAP-43 oder auf die lokale Expression von antinoczeptiven Zytokinen ( $\text{TNF}\alpha$ ,  $\text{IL-1}\beta$ ) in der Pfote mittels ICC und ISH ist Gegenstand laufender Untersuchungen.

Darüber hinaus werden die Untersuchungen auf kranke Ratten, bei denen durch Freund Adjuvans eine chronische Arthritis induziert wurde.

1<sup>st</sup> Congress of the European Society for Musculoskeletal Shock Wave Therapy (ESMST)  
01.06.1998, Izmir, Turkey

## **THE USE OF EXTRACORPOREAL SHOCK WAVES IN THE TREATMENT OF HEEL PAIN**

F.O. Steeb  
Orthopädische Praxis, Stuttgart, Germany

From September 1995 until October 1997, a total of 88 patients suffering from plantar calcaneal spur and plantar fasciitis, who had previously undergone conventional therapy without success, were treated with a lithotripter (MINILITH SL1) manufactured by STORZ. Before extracorporeal shock wave therapy was started, the patients received the obligatory minimum pretreatment in the form of insole supports, oral nonsteroidal anti-inflammatory drugs (NSAIDs) and/or oral steroid injections as well as physical therapy.

In the course of this study, the intensity of pain was assessed before and after the treatment as well as three, six and 12 months after completion of the therapy. The intensity of pain was classified on the basis of the visual analogue scale (0 – 10). All patients underwent an average of 3.5 treatment sessions. Local anaesthesia was dispensed with in 70 % of the treatments.

After completion of the treatment, 18 % of the patients declared to be entirely free from pain, whereas 42 % stated that their condition had improved considerably ( $\geq 5$  on the visual analogue scale). After three months, 24 % of the patients treated were totally free from pain and 40 % declared that their condition had improved significantly. Six months after the therapy, 30 % of the patients were entirely free from pain and 45 % had experienced a substantial improvement in their condition. These results proved to be unchanged one year after completion of the treatment.

No serious side effects were detected as a result of the therapy.

In conclusion, it can be said that the use of extracorporeal shock wave therapy (ESWT) in the treatment of heel pain is a highly successful alternative therapy method even for patients who were previously subjected to conventional treatment without success.

1<sup>st</sup> Congress of the European Society for Musculoskeletal Shock Wave Therapy (ESMST)  
01.06.1998, Izmir, Turkey

## **TREATMENT OF EPICONDYLOPATHIA RADIALIS WITH EXTRACORPOREAL SHOCK WAVE THERAPY – PRELIMINARY RESULTS**

R. de Oya  
Hospital Asepeyo, Madrid, Spain

To evaluate in a preliminary study the results of treatment of radialis epicondylopathia in a heterogeneous group of patients by a shock wave therapy.

58 patients were treated with a shock wave therapy using a machine model MINILITH SL1 STORZ. The patients were evaluated in a prospective study. The distribution of the serie was: 74% were males and 65% effort workers, being 87% of labor origin. The patients were diagnosed by clinical signs, and the average for age was 42 years old. The treatments they had previously received were the following ones: surgery 10%, rehabilitation 58%, corticoanesthetic infiltrations 70%. In 17% no previous treatment had taken place. The average time of evolution for epicondylopathia was 9 months.

So it was used a four session shock wave therapy, spaced by a period of 7 days. The number of impulses per session was 1500, using an energy of 0,03 – 0,04 mJ/mm<sup>2</sup>. The intensity of pain was evaluated with VAS before and after concluding this treatment. The results were stratified in function of the following variables: age, work type, time of evolution, previous infiltrations, rehabilitation and previous surgery. We used for comparison Chi square and Wilcoxon tests.

At the end of the treatment, 11% of the patients referred a reduction of intensity of pain major than 75%, and 24% among 50 – 75%. The variable which was statistically associated to best results was the absence of previous infiltrations. In patients who were not infiltrated, 31,3% referred a reduction of intensity of pain major than 75%, and 37,5% among 50 – 75%. The ones who showed a tendency to best results, although with no statistical value, were workers with sedentary activity, young patients and those with no previous surgeries.

The results of this study suggest the need to improve the criteria for patients selection, the application of more energy dose in each treatment, and to carry out this therapy earlier after patient evaluation.

1<sup>st</sup> Congress of the European Society for Musculoskeletal Shock Wave Therapy (ESMST)  
01.06.1998, Izmir, Turkey

## **CLINICAL RESULTS IN EXTRACORPOREAL INDUCED LITHOTRIPSY OF TENDINOSIS CALCAREA OF THE SHOULDER**

A. Brade  
Fabricius Klinik, Remscheid, Germany

### **Object:**

The study's object was to evaluate medium-term results in application of ESWT to the shoulder for integration of this treatment into the therapy concept of tendinosis calcarea.

### **Material:**

From 05/95 to 12/96 90 patients with tendinosis calcarea (43 female/27 male) were treated. The average age was 50 years (28 to 81). In 2-3 sessions with an interval of 2 weeks ESWT was applicated to the shoulder. In the follow up 70 of 90 cases were reexamined in a postapplication period of 20 months on the average.

### **Results:**

37 patients were painless, 22 had light, 11 moderate and 10 intense pain in movement and stress. Painlessness was achieved in average 6 weeks after ESWT. The range of movement was similar to the contralateral healthy shoulder in 47 cases. 65 were able to dress up easy, 50 were able to work over head with no problems and 58 to lie on the treated shoulder. For 29 patients the result of ESWT was excellent, 21 good, 10 satisfactory and for only 10 it was a failure. 57 (i.e. 81%) consider ESWT as very recommandable. Nevertheless in 3 cases of failure operative treatment was necessary.

### **Discussion:**

The range of tendinous calcium pre- vs. post-application has no influence on clinical results. Failures occure in cases of simultaneous diseases of cervical spine or the glenohumeral joint. Success can be estimated after the second session.

### **Summary:**

The use of ESWT in cases of tendinosis calcarea is a successful and serious therapeutic method having good functional medium-term results, when used in correct indication and after ineffective utilization of all conservative therapeutic measures.

1<sup>st</sup> Congress of the European Society for Musculoskeletal Shock Wave Therapy (ESMST)  
01.06.1998, Izmir, Turkey

## **THE TREATMENT OF NON-UNION BY HIGH ENERGY SHOCK WAVE THERAPY**

C. de Durante  
University Hospital, Napoli, Italy

The authors show their experiences in treatment of non unions by high energy shock wave therapy (HESWT); they use electromagnetic devices (MODULITH SLX and MINILITH SL1 by STORZ MEDICAL AG).

The therapeutic approach must consider some parameters which will be discussed individually; the X ray exams and MRI allow us to evaluate the border-line situations (evident axial deviations and/or malrotation) which represent an exclusion criteria for HESWT, and more they furnish important information for a prognostic evaluation. MRI allows to evaluate the presence of ischemic areas or local osteonecrosis near the lesion. These areas (the so-called break points) represent the sites with an altered micro circle and must be treated specifically.

The number of applications and shock wave power depend on the bone size and pressure field dimension: for large bones (femur or tibia, for example) we need more applications and more power then for the small ones (carpal scaphoid or metacarpal bones).

Table 1 reports the casuistry – in table 2 the results are shown with average follow-up of 2,5 months: Group A are the total fusion of bone, group B the partial fusion, group C the failures (no fusion):

Table 1

Humerus	9
Phalanx	18
Metacarpal	15
Carpal Scaphoid	187
Hamate	1
Ulna	21
Radius	25
Femur	30
Tibia	27
Tibia (congenital)	3
Clavicula	12
<b>Total</b>	<b>348</b>

Table 2

Total fusion	232	66,7 %
Partial fusion	68	19,5 %
No fusion	48	13,8 %

25 Jahre ARO – Jubiläums-Tagung der Assoziation für Orthopädische Rheumatologie  
04.-06.06.1998, Zürich, Switzerland

## **TENDINOSIS CALCAREA DER SCHULTER: IST DIE ESWT EINE ALTERNATIVE ?**

B. Dubs

Spital Bethanien, Institut für Sonographie, Zürich, Switzerland

Seit Herbst 1995 wenden wir die ESWT am Bewegungsapparat routinemässig in unserem Spital an. Wir führten nach gut einem Jahr eine erste Auswertung mit kritischer Betrachtung durch:

43 Patienten wurden ambulant zweimal im Abstand von 1-2 Wochen mit je 2000 Stosswellen behandelt. Voraussetzung war eine Therapieresistenz auf konventionelle Methoden wie Physiotherapie, Infiltration(en) von mindestens 3 Monaten. Ausschlusskriterien bestanden bei Vorliegen einer signifikanten Rotatorenmanschettenläsion, einer lokalen Infektion oder einer Gerinnungsstörung. Die klinischen Vorabklärungen wurden ergänzt durch Röntgenaufnahmen und eine Sonographie. Die Stosswellenapplikation erfolgte in mittlereenergetischer Technik direkt auf das Kalkdepot nach lokaler Anästhesie der umgebenden Weichteile. Die Focussierung und Behandlungskontrolle geschah mittels Fluoroskopie im zwangszentrierten Röntgen-C-Bogen. Zum Einsatz kam das Gerät MODULITH SLX von STORZ, welches normalerweise für die Nierenstein-Lithotripsie verwendet wird, aber ohne grosse Massnahmen auch am Bewegungs-apparat angewandt werden kann.

Die Behandlungen waren in der Regel leicht schmerzhaft, wurden aber gut ertragen. Nebenwirkungen traten nur in Form von lokalen passageren Hautrötungen oder kleinen Suffusionen auf.

Wir erzielten folgende Resultate:

- 25 (58,1 %) wurden absolut beschwerdefrei, voll beweglich und erlangten die volle Kraft zurück.
- 11 (25,6 %) konnten derart gebessert werden, dass nur noch gelegentliche, minime Restbeschwerden zurückblieben und keine weiteren Massnahmen erforderlich wurden.
- 7 (16,3 %) blieben kaum oder ganz unverändert und mussten schliesslich einem operativen Verfahren zugeführt werden.

Die meisten Veränderungen geschahen im Zeitraum des ersten Monats nach der ESWT, nach dem dritten Monat konnten kaum noch weitere Verbesserungen festgestellt werden. In zwei Fällen wurde 6 Monate nach der Erstbehandlung noch eine dritte Applikation durchgeführt, welche einmal erfolgreich war. In zwei weiteren Fällen wurde nach vorübergehender Beschwerdefreiheit eine erneute leichte Verschlechterung festgestellt. Interessant ist die Beobachtung, dass trotz Erlangen vollständiger Beschwerdefreiheit bei einem guten Drittel der Patienten keine Kalkresorption festgestellt werden konnte. Eine Auswertung über Lage und Form der Verkalkung wurde bei diesem ersten Kollektiv noch nicht durchgeführt. Die in der Zwischenzeit durchgeführten weiteren ESWT-Behandlungen bestätigen nach ersten Hochrechnungen die bisherigen Erfolgszahlen, welche im übrigen auch mit der internationalen Literatur gut übereinstimmen.

Die ESWT ist verhältnismässig günstig und kaum invasiv. Insgesamt ist die ESWT bei der Tendinosis calcarea der Schulter eine interessante Alternative, und vermag mit den Resultaten des Needlings sehr gut mithalten. Ihr Einsatz sollte deshalb unter Berücksichtigung der Kriterien vor einem allfälligen operativen Einsatz geprüft werden.

Jahrestagung der Österreichischen Gesellschaft für Physikalische Medizin  
und Rehabilitation  
23.-24.10.1998, Steyr, Austria

## **DISPERGIERENDE EXTRAKORPORALE STOSSWELLENTHERAPIE BEI MUSKELFUNKTIONS- STÖRUNGEN**

H. Lohse-Busch, M. Kraemer, U. Reime, M. Riedel  
Theresienklinik, Bad Krozingen, Germany

In den letzten 36 Monaten wurden rund 950 bewegungsgestörte Kinder und ca. 120 Erwachsene mit niedrigerenergetischen, nicht fokussierten, also dispergierenden extrakorporalen Stosswellen (ESW) mithilfe eines modifizierten Lithotriptors MINILITH SL 1 der Firma STORZ MEDICAL AG behandelt.

Neben spastischen Bewegungsstörungen der Kinder kamen auch experimentell Muskelfunktionsstörungen bei banalen Lumbalgien, Arthrogryposis multiplex congenita, Myopathien und Multipler Sklerose zur Behandlung.

Wie aus einer kleinen Doppelblinduntersuchung (11 spastisch bewegungsgestörte Kinder, davon 6 scheinbehandelte) hervorgeht, tritt bei der Monotherapie mit ESW die Muskelentspannung unabhängig von der Tonusausgangslage auf, sodass besonders Kinder mit hypotoner Ausgangslage zeitlich begrenzt den stützenden spastischen Hypertonus verlieren. Eine kleine neuropsychologische Untersuchung zeigt Tendenzen, dass die Kinder auch im Bereich ihrer kognitiven Fähigkeiten aufgrund der verbesserten Sensomotorik profitieren.

Bei 35 Kindern und Jugendlichen mit hauptsächlich spastischen Bewegungsstörungen nahm der Bewegungsumfang der Hüftgelenke durchschnittlich um 17°, der Kniegelenke um 12,3° und der Sprunggelenke um 7,1° bereits nach einer Behandlung jeweils statistisch signifikant zu. Spastische Kokontraktionen, muskuläre Steifigkeit und myofasziale Viskoelastizität nahmen ebenso wie dyskinetische und ataktische Symptome ab.

Es scheint, dass sich unabhängig von der Ätiologie besonders die muskuläre Steifigkeit und die spastisch bedingte Hypertonie deutlich mildern lassen. Muskuläre Kontrakturen gehen zurück. Neuere Untersuchungen legen den Schluss nahe, dass die ESW die für die muskuläre Steifigkeit verantwortlichen, persistierenden Aktinomyosinbrücken lösen und so zu verbesserter Beweglichkeit führen.

ESW lösen Aktionspotentiale an Nerven aus und schaffen damit vermehrte propriozeptive Affenzen im motorischen System. Sie steigern auch reflektorisch die Durchblutung der behandelten Gewebe.

Die Behandlung ist schmerzfrei. Unerwünschte Wirkungen wurden nicht beobachtet. Die biomechanischen Verbesserungen halten bei unbeeinflusstem neurologischen Grundleiden mehrere Wochen an. Die Zeit kann zur Anbahnung verbesserter Bewegungsmuster genutzt werden.

47. Jahrestagung der Vereinigung Süddeutscher Orthopäden e.V.  
29.04.-02.05.1999, Baden-Baden, Germany

## **EINFLUSS „NIEDERENERGETISCHER“ ESWT AUF NEUROTRANSMITTER UND ENDOGENE OPIOIDE**

M. Haake, A. Thon, M. Bette, E. Weihe  
University Hospital, Marburg, Germany

Für die analgetischen Effekte der niederenergetischen ESWT in ihrer Anwendung als orthopädische Schmerztherapie werden verschiedene neuronale Wirkmechanismen diskutiert (Gate-control-Theorie, Forward Inhibition, Endogene Schmerzkontrolle, c-Faser-Destruktion). Der Nachweis des tatsächlichen Mechanismus steht bislang noch aus.

Ausgehend von der Richtigkeit dieser neurophysiologischen Theorien wäre dann auch eine Auswirkung der ESWT auf molekularer neuroimmunologischer Ebene zu fordern. Dies wurde an 132 gesunden Ratten überprüft.

Analog zur Schmerztherapie beim Menschen wurden die Rattenpfoten mit ESWT einer Energieflussdichte von 0,04 bzw. 0,11 mJ/mm<sup>2</sup> bei 1000 Impulsen pro Sitzung und 1maliger bzw. 3maliger Applikation im Abstand von zwei Tagen behandelt. Verwendet wurde ein STORZ MINILITH SL 1.

Es zeigten sich im Rückenmark bei Tötung 4 h oder 72 h nach ESWT keine Veränderung der Transmitterexpression (NPY, SR, CGRP, TH, VIP), der Opioidexpression (DYN, MRGL) oder der Regulation von Zytokinen (IL1- $\beta$ ) sowie der Transkriptionsfaktoren (c-fos).

Ebenso konnte in der behandelten Pfote keinerlei Veränderung der Transmitterexpression (CGRP, PGP, NPY, SP, TH), der Regulation von Zytokinen (IL1- $\beta$ ), Nervensprossungsfaktoren (GAP 43), Transkriptionsfaktoren (c-fos) oder Durchblutung (HVMAT-2, VACHT) gemessen werden.

Es fand sich somit weder ein lokaler noch spinaler Effekt auf die antinozizeptiven oder nozizeptiven Systeme. Neurodestruktionen im Therapiegebiet konnten andererseits ausgeschlossen werden.

Die bislang allgemein als Wirkmechanismen der niederenergetischen ESWT postulierten neurophysiologischen Theorien sind unserer Meinung nach vermutlich nicht zur Erklärung auf neurologischer Ebene ausreichend. Sollte die ESWT solche neurophysiologischen Effekte mit länger dauernder Analgesie hervorrufen, so müssten auch Veränderungen in den untersuchten Transmitter- und Opioidsystemen als indirekter Nachweis feststellbar sein.

47. Jahrestagung der Vereinigung Süddeutscher Orthopäden e.V.  
29.04.-02.05.1999, Baden-Baden, Germany

## **DIE ESWT IM RAHMEN DER ORTHOPÄDISCHEN SCHMERZTHERAPIE: 2-JAHRES-ERGEBNISSE IN 899 FÄLLEN**

W. Brunner, R. Thüringer, G. Ascher, A. Neuking, A. Solleder, F. Schmidt-Hoensdorf,  
W. Bärtl, K. Vetter  
Orthopädische Praxen, Mainburg, Germany

Von 1/96 bis 12/98 wurden insgesamt 899 konservativ bereits austherapierte bzw. bereits vorher operierte Patienten mit therapieresistenten Erkrankungen am Bewegungsapparat mit durchschnittlich 3 Sitzungen in 14tägigen Abständen in 7 orthopädischen, chirurgischen Praxen behandelt. Indikationsstellungen waren Achillodynie, Epicondylopathia ulnaris und radialis, Fersensporen, Supraspinatussyndrom, Tendinitis calcarea der Schulter sowie Trochantertendinose und Pseudarthrosen. Die Schmerzintensität wurde anhand einer visuellen Analogskala vor der Behandlung, 3 und 6 Monate sowie 2 Jahre nach der Behandlung ermittelt.

In 28,7 % konnte völlige Beschwerdefreiheit erreicht werden, in weiteren 33,9 % wurde über eine mindestens 50 %ige Schmerzreduktion berichtet. 56 Patienten (6,3 %) mussten sich trotz ESWT einer Operation unterziehen und wurden als Therapieversager gewertet. Besonders gute Ergebnisse (in über 70 % mindestens 50 %ige Beschwerdebesserung) konnten beim Fersensporen sowie bei der Tendinitis calcarea erzielt werden. Im Durchschnitt konnte eine Reduktion der Schmerzintensität von 8,4 auf der visuellen Analogskala auf 3,9 nach 3 Monaten, 3,3 nach 6 Monaten und 3,2 nach 2 Jahren erreicht werden.

Dies lässt den Schluss zu, dass bei den o.g. Indikationsstellungen eine gute bis sehr gute dauerhafte Schmerzreduktion erreicht werden kann. Aus unserer Sicht ist daher zu fordern, nach Fehlschlägen einer ausgiebigen konservativen Therapie dem Patienten die extrakorporelle Stosswellentherapie als Alternative zur Operation anzubieten. Mit dieser Methode ist das schmerztherapeutische Spektrum der Orthopädie in Deutschland wesentlich bereichert worden.

2<sup>nd</sup> International Congress of the European Society for Musculoskeletal Shock Wave Therapy (ESMST), 27.-29.05.1999, London, Great Britain

## **TREATMENT OF HUMERAL EPICONDYLITIS WITH LOW ENERGY SHOCK WAVES**

S. Gigliotti, S. Russo, C. de Durante, R. Canero  
University of Naples „Federico II“, Napoli, Italy

Although many treatments have been proposed, the conservative therapy for lateral epicondylitis is not at present successful in every case. This study examines the effects of low energy shock wave therapy in patients affected by „tennis elbow“ in the acute phase and after unsuccessful alternative conservative treatment. Since 1992 we have treated 226 patients: 214 affected by chronic epicondylitis and 52 suffering from acute pain in the laterale epicondyle. Shock wave therapy was applied in four sessions at weekly intervals using 1500 impulses and an energy from 0.03 to 0.07 mJ/mm<sup>2</sup>. Therapy was carried out with continuous ultrasound localisation focussing treatment on the osteo-tendinous insertion.

At 6 month follow-up in patients with chronic pain there was a very good result (reduction of pain from 90% to 100%) in 64 cases (30%) and a good result in 103 cases (48%). In the same period in patients with acute pain there were very good results (41%) or good results (59%).

At one year follow-up we reported a tendency towards a possible further improvement of results.

2<sup>nd</sup> International Congress of the European Society for Musculoskeletal Shock Wave Therapy (ESMST), 27.-29.05.1999, London, Great Britain

## **TEN YEARS EXPERIENCE WITH SHOCK WAVE THERAPY OF RADIAL AND ULNAR EPICONDYLAR DISORDERS**

J. Haist  
Orthopädische Praxis, Wörrstadt, Germany

Since the beginning of the 1990s shock wave therapy has been tested in various musculoskeletal disorders. Initially shock wave therapy was used to treat pseudarthrosis as well as slow healing fractures at a few medical centres. Later on shock wave therapy was employed in soft tissue pain disorders like radial and ulnar epicondylar disorders or for calcification of the rotator cuff.

Since 1990 we have used the shock wave therapy in the treatment of radial and ulnar epicondylar disorders. Between March 1990 and January 1999, we treated 1614 patients with radial and ulnar epicondylitis. Up to now 1406 patients afflicted with radial epicondylitis (1098) or ulnar epicondylitis (308) have been included in the follow-up examinations performed 3 to 100 months after the last treatment. All patients had been treated for at least 3 months with various conservative or operative methods. A total 4077 sittings were performed, on an average of 2.9 sittings each patient. The shock wave therapy was performed with an intermediate energy level between 0.08 and 0.12 mJ/mm<sup>2</sup>. No complications were observed.

The results for treatment were very good and good results, in 72% of the patients with radial epicondylitis and 62% of the patients with ulnar epicondylitis. The results confirm that shock wave therapy of radial and ulnar epicondylar disorders offers an alternative to established conservative and operative techniques.

2<sup>nd</sup> International Congress of the European Society for Musculoskeletal Shock Wave Therapy (ESMST), 27.-29.05.1999, London, Great Britain

## **THREE YEARS RESULTS OF EXTRACORPOREAL SHOCK WAVE THERAPY (ESWT) WITH 272 AMATEUR AND COMPETITIVE ATHLETES WITH EPICONDYLITIS HUMERI RADIALIS (EHR)**

D. Steeger von Keitz, A. Lowe  
Orthopädische Praxis, Rüsselsheim, Germany

Over the years, the analgetic effects of extracorporeal shock wave therapy (ESWT) have become an alternative therapy in the treatment of epicondylitis humeri radialis (EHR). The following study shows the results for competitive athletes who have epicondylitis humeri radialis (EHR).

The age of the participants ranged between 23 to 60 years. 3 treatments were performed in a weekly interval. 1500 electromagnetically induced low energy (0.06 mJ/mm<sup>2</sup>) shock waves were applied to the involved epicondylus.

The results show that almost immediately after the extracorporeal shock wave therapy (ESWT), 171 patients (approx. 63%) had good to very good reports, a mild improvement was seen with 74 patients (27.2%) and no change was reported with 27 patients. After a 6 weeks waiting period, the first check was completed. It showed a rise in good to very good results to 72.1% (196 patients). The patients with no change did not alter even after the 6 weeks follow-up. After 6 months there was again a slight rise to 76.1% reporting good to very good results. The groups with fair to unsatisfactory results could not be completely evaluated because 17 patients had undergone an operation. 36 of the remaining patients reported a slight improvement and 12 patients had no change. After 3 years, almost 72% of the patients had good to very good results. A recurrence of epicondylitis humeri radialis (EHR) was reported with only 12 patients (4.4%). The group of patients with fair/unsatisfactory results showed that 23 patients underwent an operation. Negative side effects or serious adverse events (SAE) were not reported.

2<sup>nd</sup> International Congress of the European Society for Musculoskeletal Shock Wave Therapy (ESMST), 27.-29.05.1999, London, Great Britain

## THE TREATMENT OF SHOULDER PERIARTICULAR CALCIFICATION BY SHOCK WAVES

C. de Durante, S. Russo, S. Gigliotti, B. Corrado  
University of Naples „Federico II“, Napoli, Italy

The authors present the preliminary results of their study on the treatment of shoulder periarticular calcification with medium energy shock waves. Ten patients suffering from subacromial impingement syndrome, with radiographic evidence of calcification inside the supraspinatus tendon and subacromial bursa, were studied. The MRI showed a rotator cuff lesion in two cases. All the patients showed a painful reduction of shoulder abduction and external rotation.

The treatment consisted of four sessions of medium energy shock waves (power from 0.2 to 0.4 mJ/mm<sup>2</sup>), one per week, each session of 2500 shots. Follow-up immediately after treatment and one month later showed in 80% of cases a reduction of pain with a total disappearance of pain in 5 cases at 1 month follow-up. The two patients with a supraspinatus tendon lesion experienced a poor clinical result. X-rays one month after treatment showed a total disappearance of calcification in 5 cases, partial resorption in 3 cases and no variation in the 2 patients with a supraspinatus tendon lesion. MRI permitted accurate identification of the tendon degeneration and gives us the possibility to isolate those patients with large rotator cuff lesions that in our opinion represent a contraindication to this treatment. The authors consider the technique a valid treatment method of subacromial impingement syndrome with periarticular shoulder calcifications and in those patients without associated tendon damage.

2<sup>nd</sup> International Congress of the European Society for Musculoskeletal Shock Wave Therapy (ESMST), 27.-29.05.1999, London, Great Britain

## SHOCK WAVES IN THE TREATMENT OF CARPAL SCAPHOID NON-UNION

B. Corrado, S. Russo, S. Gigliotti, C. de Durante, R. Canero  
University of Naples „Federico II“, Napoli, Italy

The authors present their experience in the treatment of carpal scaphoid non-union with shock waves.

The first applications go back to 1994 and since then about 200 cases of carpal scaphoid non-union have been treated and verified. The applied treatment programme has consisted of one or two cycles of therapy, each one of 4 applications of 4000 shock waves at 48-hour intervals. After each application the arm has been immobilized in a cast.

Patient selection has been made by means of X-ray and MRI; patients with unclosed fractures, carpal scaphoid bad atrophy or total deficit of carpal scaphoid vascularization have been left out. Controls at the 50 day medium follow up have shown the following results:

- 48 % total healing
- 37% partial healing
- 15% no healing.

However, in about all cases MRI has pointed out the renewal of carpal scaphoid vascularization after shock wave treatment.

2<sup>nd</sup> International Congress of the European Society for Musculoskeletal Shock Wave Therapy (ESMST), 27.-29.05.1999, London, Great Britain

## TEN YEARS EXPERIENCE WITH SHOCK WAVE THERAPY OF PSEUDARTHROSIS

J. Haist  
Orthopädische Praxis, Wörrstadt, Germany

Since the beginning of the 1990s shock wave therapy has been tested in various musculoskeletal disorders. Initially shock wave therapy was used to treat pseudarthrosis as well as slow healing fractures at a few medical centres. Later on shock wave therapy was employed in soft tissue pain disorders like radial and ulnar epicondylar disorders or for calcification of the rotator cuff.

Since 1989 we use the shock wave therapy in the treatment of pseudarthrosis as well as of delayed bone union. Between 1989 and 1998 we treated 164 patients with pseudarthrosis and 36 patients with delayed bone union. The shock wave therapy was used a single time with 3000 up to 110000 impulses and a high energy level. In 128 cases we saw a complete bone consolidation. The best results could be seen in szinitigraphic hypertrophic pseudarthroses.

The results show that the shock wave therapy of pseudarthrosis and delayed bone union offers an alternative to the established conservative and operative therapeutical techniques.

2<sup>nd</sup> International Congress of the European Society for Musculoskeletal Shock Wave Therapy (ESMST), 27.-29.05.1999, London, Great Britain

## SHOCK WAVE TREATMENT OF HIP NECROSIS: PRELIMINARY RESULTS

S. Russo, S. Gigliotti, C. de Durante, D. Andretta, O. Galasso  
University of Naples „Federico II“, Napoli, Italy

The authors show a preliminary paper about 45 hip necroses treated with ESWT. The patients were evaluated and then monitored by X-ray, MRI, TPBS and TC. All the 45 selected patients, age between 26 and 52, belonged to classes 0,1 and 2 of Arlet and Ficat (1980/85).

An electromagnetic device equipped with an X-ray, a focal distance of 16.5 cm and a focal point of 6 x 28 mm was used. The power was between 0.26 and 0.69 mJ/mm<sup>2</sup>. The critical areas of the hips were shot in different applications on the back side, on the lateral side with +45° and +135° of inclination, and on the front side. An early pain reduction equivalent to a 5-70% was already observed after the first application.

The 6 months follow-up showed a total pain disappearance in 39 patients, a pain decrease (beyond 70% of the initial value) in 4 cases and no results in 1 patient. In all the treated patients the MRI always showed a marked variation of the signal from the critical areas due to the induced blood flow increase. The MRI signal variations were proportional to the pain reduction. The TPBS showed a further increase of the interstitial phase due to the post-treatment edema increase in the early follow-up and a tendency to the normalization of the curve, both in interstitial and metabolic phase in the late follow-up.

2<sup>nd</sup> International Congress of the European Society for Musculoskeletal Shock Wave Therapy (ESMST), 27.-29.05.1999, London, Great Britain

## EXTRACORPOREAL SHOCK WAVE THERAPY IN THE TREATMENT OF DUPUYTREN'S AND LEDDERHOSE'S CONTRACTION

J. Haist  
Orthopädische Praxis, Wörrstadt, Germany

Since 1992 shock wave therapy is used by various urologists in the therapy of the so-called induratio penis plastica with good results. Because the induratio penis plastica and the palmar and plantar fibromatous diseases show similar pathomorphological alterations a few orthopaedic centres in Germany propagate the shock wave therapy in the treatment of the contraction of the plantar and palmar fascia. For that a prospective study should prove the efficiency of the shock wave therapy. Totally 40 patients afflicted with Dupuytren's contracture and 15 patients afflicted with Ledderhose's disease have been treated with shock wave therapy.

The shock wave therapy was used three times with 2500 single impulses and an energy level of 0.42 mJ/mm<sup>2</sup> (high energy level). Follow-up examinations have been performed 4 weeks, 16 weeks and 6 months after the last treatment.

The results were subdivided in degree of contraction, mobility and level of pain. In opposite to the urological experiences we could not see a significant benefit in mobility, pain or degree of the fibromatous contractures. As conclusion of our results we can not advice the shock wave therapy in the therapy in the Dupuytren's or Ledderhose's contracture.

XIV Congress of the European League Against Rheumatism (EULAR)  
06.-11.06.1999, Glasgow, Scotland

## TREATMENT OF SHOULDER PERIARTICULAR CALCIFICATION BY MEDIUM ENERGY SHOCK WAVES: 10 CASES REPORT

B. Corrado, S. Russo, S. Gigliotti, C. de Durante  
University of Naples „Federico II“, Napoli, Italy

The authors present the preliminary results of their study about the treatment of shoulder periarticular calcifications by medium energy shock waves.

Ten patients suffering from subacromial impingement syndrome, with radiographic evidence of calcifications inside supraspinatus tendon and/or subacromial bursa were studied. The MRI showed a rotary cuff lesion in two cases; all the patients presented a painful reduction of shoulder abduction and extrarotation. The treatment consists of four sections of medium energy shock waves (power from 0.2 to 0.4 mJ/mm<sup>2</sup>), one for week, every section of 2500 shots.

The follow-up immediately after treatment and one month later shows in 80% of cases a reduction of pain (total disappearance of pain in 5 cases at one month follow-up); the two patients with supraspinatus tendon total lesion did not get good clinical results. X-ray exam one month after treatment shows a total disappearance of the calcification in 5 cases, a partial reabsorption of the calcification in three cases, no variation in two cases.

MRI allows to identify accurately the tendon degeneration and gives us the possibility to point out the large rotatory cuff lesion that represent in our experience a contraindication to the treatment.

The authors consider the technique a valid treatment method for subacromial impingement syndrome with periarticular calcifications.

XIV Congress of the European League Against Rheumatism (EULAR)  
06.-11.06.1999, Glasgow, Scotland

## THE TREATMENT OF ENTHESIOPATHY SUCH AS PLANTAR FASCIITIS, TENNIS AND GOLFERS ELBOW AND SIMILAR WITH EXTRACORPOREAL SHOCK WAVES USING A MODIFIED LITHOTRIPTER

G.F. Schmitgen, M.J. Burke  
Buruley General Hospital, Buruley, Great Britain

### Objective

We want to present a new conservative treatment for enthesiopathies and our results in comparison with those found in the literature.

### Method

We have been treating over one hundred patients with chronic enthesiopathies, the vast majority of which had undergone various conservative and surgical treatments without success prior to receiving extracorporeal shock wave treatment (ESWT). Clinical symptoms were assessed prior to treatment, at the beginning of each session and in the months following the completion of ESWT. Patient groups were treated on two different lithotripters with different energy levels.

### Results

More than 80% had good to excellent results. The results are compared with results using other treatments and from other centres. Non-responders were analysed.

### Discussion

The treatment of enthesiopathies with ESWT using a modified lithotripter is a fairly new technique, which gives good to excellent results. It offers an additional, safe, non-invasive tool for treating certain conditions of chronic soft tissue pathologies. In many cases it seems to be superior to other therapies and should be considered as treatment of choice whenever other treatments have failed or perhaps even as treatment of choice, especially as no long term side-effects have been seen so far and is very cost effective in relation to the traditional treatments.

## A PROSPECTIVE, BLINDED, RANDOMISED CONTROL TRIAL ASSESSING THE USE OF DIFFERENT ENERGY EXTRACORPOREAL SHOCK WAVE THERAPY FOR CALCIFYING TENDONITIS

A. Hearnden, M.C. Flannary  
Royal Surrey County Hospital, Surrey, Great Britain

### Objective

There are several treatment modalities for calcific tendonitis of the shoulder. Over the last eight years extracorporeal shock wave therapy (ESWT) has been shown to be effective as a non invasive therapy. However, many of the trials have been criticised for not achieving necessary scientific standards. We report on the result of a prospective, blinded, randomised control trial on 34 patients, randomised into three groups. The aim of the trial was:

1. to assess the effectiveness of high energy ESWT against a control group
2. to observe pain levels experienced during and after the treatment, and the time for return to work
3. to record the maximum, mean energy levels tolerated by patients without injecting local analgesia.

### Method

The patients were selected from 39 consecutive referrals with Gartner type I or II calcific deposits on Xray, complaining of shoulder pain secondary to supraspinatus tendonitis (diagnosed using MRI or USS), who would classically be offered surgery. Other criteria for inclusion in the trial were: a history of pain for a period greater than 12 months and a failure of conservative therapy. Patients with rotator cuff rupture, local arthritic changes or generalised polyarthropathies, neurogenic syndromes, pregnancy, infection or coagulation disorders were excluded from the trial. The control group I (n=10) received a sham treatment of only 20 shocks with a negligible energy flux density of 0.03 mJ/mm<sup>2</sup>. Group II (n=17) received 2000 shocks at 0.25 mJ/mm<sup>2</sup> (high energy) following local injection with 20 mls 0.5% marcaine. Group III (n=7) received 2000 shocks, on three occasions 2 weeks apart, at the maximum energy level tolerable without the use of local anaesthesia. All patients were assessed pre-treatment and followed up at 6 and 26 weeks with an Xray and ultrasound scan. Subjective improvement was classified as worse, no change, slight, significant improvement and complete resolution, objective improvement was measured using Constant Morley shoulder assessment score. Each patient was asked to mark on a pain scale his level of discomfort during treatment and each day afterwards, they also indicated when they returned to work.

### Results

The control group experienced no significant subjective or objective improvement. 88% of patients in group II attended the follow up. 47% of patients experienced significant improvement or complete resolution. We found that all patients with deposits smaller than 1 cm experienced no improvement, whereas those with larger deposits benefited most. 40% of patients experienced complete resorption of the calcific deposit; there was no clear correlation between resorption and outcome. 82% found ESWT painful and half of these experienced pain levels of 7/10 (very bad, severe) after treatment, however 87% had returned to, or improved on their pre-treatment pain levels 2 days after therapy. 100% of those in work returned the following day. 64% complained of bruising over the shoulder (range 2 to 10 cm). The patients in group III tolerated a mean energy flux density of 0.07 mJ/mm<sup>2</sup> (range of 0.04 to 0.11 mJ/mm<sup>2</sup>) without analgesia. Complete resolution occurred in one patient (14%), but there was no significant rise in the constant score for the group. Further discussion includes the cost implications of ESWT and the emergence of arthroscopic debridement as a minimally invasive day case procedure.

3<sup>rd</sup> Congress of the International Society for Musculoskeletal Shock Wave Therapy (ISMST)  
01.-03.06.2000, Naples, Italy

## THE TREATMENT OF SHOULDER PERIARTICULAR CALCIFICATIONS BY SHOCK WAVES

C. de Durante, S. Russo, S. Gigliotti, C. Pecoraro  
University of Naples Federico II, Naples, Italy

### Objective

The authors present the results of their study about the treatment of shoulder periarticular calcifications by shock waves, trying to focalize the limits of the applications in this kind of pathology.

### Method

25 patients suffering from subacromial impingement syndrome, with radiographic evidence of calcifications inside supraspinatus tendon, were studied. All patients presented a painful reduction of shoulder abduction and extrarotation. MRI showed a rotatory cuff lesion (total interruption of supraspinatus tendon) in five cases. The treatment consisted of four sessions of medium energy shock waves (power from 0.2 to 0.4 mJ/mm<sup>2</sup>), one per week, 2500 shots for each session.

### Results

The follow-up immediately after the treatment and one month later showed in 80% of cases a reduction of pain (total disappearance of pain in 12 cases at one month follow-up). The five patients with supraspinatus tendon lesion got insatisfactory clinical results. The Xray exams one month after treatment showed a total disappearance of the calcification in 13 cases, a partial reabsorption in 8 cases (one of these with tendon lesions), no variation in 4 cases (all patients with tendon lesions).

### Discussion

In our experience, a rotatory cuff lesion always represents a contraindications to shock wave treatment.

3<sup>rd</sup> Congress of the International Society for Musculoskeletal Shock Wave Therapy (ISMST)  
01.-03.06.2000, Naples, Italy

## A PROSPECTIVE RANDOMISED STUDY COMPARING SHOCK WAVE THERAPY AND STEROID INJECTION IN THE TREATMENT OF TENNIS ELBOW

M.A. Crowther  
Southmead Hospital, Bristol, Great Britain

### Objective

Lateral epicondylitis of the elbow (tennis elbow) affects 4 adults per 1000 annually. The optimum management is unclear. With the help of UMS (United Medical Systems) we conducted a randomised prospective study to compare shock wave therapy with local anaesthetic and steroid injection in the treatment of lateral epicondylitis of the elbow.

### Method

The study was dual centred at Cheltenham General Hospital and Southmead Hospital in Bristol. Local ethics approval was gained and adult patients with classic symptoms and no invasive treatment in the previous 12 months were recruited via general practitioners. Patients were assessed, consented and randomised for treatment. Pain scores were recorded at each visit to the clinic. The study looked at 73 patients with average age 49 (range 27 to 69). 48 patients underwent shock wave therapy with the STORZ MINILITH SL1. Each patient had three sessions of 2000 shocks one week apart. 25 patients underwent injection of 20 mg triamcinolone with 1% lignocaine. All patients were seen and assessed at 6 weeks and 3 months. Further telephone follow-up was performed at 9 or 12 months. Results were statistically analysed.

### Results

At 6 weeks there was a significant difference with pain scores for the injection group falling from 66 to 21 compared to the shock wave group 61 to 35. Using pain clinic criteria for success as 50% reduction in pain, the results were assessed at 3 months. 84% of the injection group and 60% of the shock wave group were successful. Longer term results have led us to conclude that although injection is more effective, shock wave therapy is certainly a useful alternative in the treatment of lateral epicondylitis.

3<sup>rd</sup> Congress of the International Society for Musculoskeletal Shock Wave Therapy (ISMST)  
01.-03.06.2000, Naples, Italy

## CHRONIC ACCHILLODYNIA. TREATMENT WITH EXTRACORPOREAL SHOCK WAVES

O. Galasso, C. de Durante, S. Russo, S. Gigliotti, B. Corrado  
University of Naples Federico II, Naples, Italy

### Objective

Shock wave therapy, originally devised to break renal calculi, has been successfully employed in orthopaedics and traumatology. The efficacy and the fast effect have won it an extensive place in the treatment of tendon diseases, especially in athletes.

### Method

We present a prospective investigation with this technique in the treatment of 23 patients (15 male, 8 female; mean age 51.4 years; mean duration of complaints 27.4 months) suffering from chronic achillodynia. In these patients conservative therapy had been unsuccessful: 13 patients had local infiltrations with corticosteroids, 9 underwent physiotherapy, 9 were subjected to ultrasound, 7 patients used insoles, all patients had NSAIDS oral medication.

Patients had been subjected to ultrasound investigation and radiographic examination before treatment started. Achilles tendon ruptures or partial tears and patients that underwent surgical treatment were excluded. Three patients showed upper heel spur.

An electromagnetic cylinder lithotripter provided with ultrasound aiming (MINILITH SL1, STORZ MEDICAL AG) was used. The epicentre of pain was marked sonographically and treated with 2000 impulses with 0.24 mJ/mm<sup>2</sup>. No anaesthesia was used. An assessment of pain by means of a visual analogue scale ranging from zero (no pain) to ten (maximal pain) was established before and six months after treatment.

### Results

Six months after therapy 13 patients out of 23 referred a reduction of pain that was lower than 30%, nine patients referred a reduction of pain between 50% and 70%, one patient was satisfied with the result.

### Discussion

Shock wave therapy is a useful procedure for treating acute pain, especially in athletes. Its value in chronic achillodynia is restricted however. Nevertheless, shock wave therapy should be administered before resorting to surgical treatment.

3<sup>rd</sup> Congress of the International Society for Musculoskeletal Shock Wave Therapy (ISMST)  
01.-03.06.2000, Naples, Italy

## CHRONIC ACHILLODYNIA TREATMENT WITH ESWT

B. Zillner, S. Schmidtberger, A. Neuhold, D. Plattner  
Orthopaedic Doctors, Vienna, Austria

### Introduction

According to our experience injection of local anaesthetic and/or steroids in/around the chronic inflamed peritendineon of Achilles tendons (AST) relieves pain immediately. Pain relieve lasts from days to years. First publications using ESWT for chronic AST problems report good longterm results even after conservative treatment has failed.

### Method

We treated the peritendineon of 16 AST using ESWT. Patients had a 6 months to 30 years history of pain, swellings, inability to perform sports, failed treatments. Age was 27 to 85. All of them practised sports very actively before getting an AST problem. To focus the inflamed areas a mobile therapy head with sonographic localisation by inline scanner was used. Painful areas were found and treated until pain relieved. Average treatment time was 60 min. 1 to 4 sessions using 2700 impulses with an average energy flux density of 0.08 mJ/mm<sup>2</sup> were performed. Sonographic measurement of AP-diameter of AST was carried out before ESWT treatment, immediately after, after 5-7 months and after 12 months. No other treatment or medication was allowed.

### Results

There was a significant decrease of the AP-diameter before/after 5-7 months and before and after 12 months. None of the AP-diameters decreased under 6 mm. 14 patients were back to sports after the end of the therapy and still after 12 months. The treatment success seems to be related to a thorough selection of patients.

3<sup>rd</sup> Congress of the International Society for Musculoskeletal Shock Wave Therapy (ISMST)  
01.-03.06.2000, Naples, Italy

## PERSONAL EXPERIENCE WITH ESWT IN MUSCULOSKELETAL ACUTE LESIONS DURING FOOTBALL WORLD CUP 1998 IN FRANCE

S. Gigliotti, S. Russo, C. de Durante, A. Ferretti\*  
University of Naples Federico II, Naples, Italy  
\*University of Rome La Sapienza, Rome, Italy

We think that the shock wave therapy has its correct indication on chronic cases of tendinitis and that acute lesions of soft tissues can be treated successfully by traditional therapies. However, the use of ESWT can be very advantageous in treatment of painful acute lesions of muscles or tendons during important sport events in order to allow the athletes to decrease time of recovery and to allow them to train and to play without pain. Our experience during the last Football World Cup allows us to make some comments useful to a correct application of ESWT.

We have treated 13 Italian football players (6 insertional tendinopathies in reacute phase, 2 osteo-periosteal contusions, 3 muscle contractures, 2 post-traumatic acute tendinitis, 1 acute bursitis and 1 muscle fibrosis). Main problem was impossibility to use the protocols of treatment: high number of shots (3000) at a very low energy (from 0.003 to 0.035 mJ/mm<sup>2</sup>), two daily sessions in order to utilise only the analgesic and anti-inflammatory effects induced by shock waves. We have recorded very good results in 2 osteo-periosteal contusions, in 3 muscle contractures. Good results in 5 insertional tendinopathies in reacute phase and in 1 bursitis. Poor results in 1 insertional tendinopathy and in 1 muscle fibrosis.

3<sup>rd</sup> Congress of the International Society for Musculoskeletal Shock Wave Therapy (ISMST)  
01.-03.06.2000, Naples, Italy

## NON-UNIONS TREATMENT AND RESULTS

M. Nigrisoli, V. Bosco  
Hospital Villa Toniolo, Bologna, Italy

### Method

From May 1997 to July 1999 we treated 26 non-unions in 25 patients after 6 months or more from trauma or from surgical procedure. Our cases include 21 fractures: 2 cases at humerus, 4 at ulna, 2 at radius (including 1 forearm), 5 at scaphoid, 4 at femur, 3 at tibia and 1 at sesamoid bone of the foot. We have also treated 1 first metatarsal osteotomy, 3 ankle joint and 1 talar-navicular arthrodeses. Mean age was 48 (range 16-60), 11 men and 14 women. The device currently used is the MODULITH (STORZ MEDICAL AG). Our protocol includes two consecutive treatments after 3/6 days with 3000-40000 shocks per focal area at 1 mJ/mm<sup>2</sup> (level 8-9). All patients were treated in outpatient clinic without anaesthesia and with just simple analgesia (Remifentanyl chloridrate). Ten minutes after the treatment the patient can sit and is able to go home after ½ hour. All patients had a previous stable surgical synthesis or a cast applied after the shock wave therapy. The patients have been controlled after 2 months with a program of second or even third treatment cycle in case of failed procedure.

### Results

Fifteen non-unions and the first metatarsal osteotomy (61.5%) healed with this technique. Four patients performed a second treatment cycle and 1 even a third cycle. The other 10 cases (38.5%) missed consolidation and needed or will need further surgical treatment. From an examination of our failed cases we can differentiate two groups: the first one includes 3 arthrodeses (tibia-talar joint) which in consideration of the nature of the disease (2 poliomyelitis and 1 patient in dialysis) received a wrong indication. The second group includes 6 patients who refused a second treatment cycle. The case of sesamoid non-union of the foot did not recover after a second treatment cycle.

3<sup>rd</sup> Congress of the International Society for Musculoskeletal Shock Wave Therapy (ISMST)  
01.-03.06.2000, Naples, Italy

## AXIAL EXTERNAL FIXATION PLUS HIGH ENERGY SHOCK WAVES IN THE TREATMENT OF UNSTABLE LEG NON UNION

F. Cozzolino, B. Corrado, M. Izzo, M. Borrelli, S. Russo, S. Gigliotti, C. de Durante  
University of Naples Federico II, Naples, Italy

### Introduction

Treatment of limb non-unions is still an uncertain and hard problem for the orthopaedic surgeon. Factors that could bring a non-union are many, but the most common is the inadequate or scanty reduction. Non-union healing can often be achieved by fracture's stumps stabilization.

### Method

Since 1994 20 patients with aseptic and unstable leg non-union have been treated by the fitting of an axial external fixator (associated or not with a fibula osteotomy) followed by one or two high energy shock wave cycles, each one consisting of 4 applications of 4000 shots at an energy level between 0.6 and 1 mJ/mm<sup>2</sup>.

### Results

A total consolidation after 4 months has been achieved in about 100% of cases. Undesired effects never have been observed.

### Conclusions

The association of axial external fixation and high energy shock waves is a good tool in the management of unstable and aseptic leg non-unions. Healing length is smaller compared with other treatment procedures. Even ipovascularized non-unions can be treated with success.

3<sup>rd</sup> Congress of the International Society for Musculoskeletal Shock Wave Therapy (ISMST)  
01.-03.06.2000, Naples, Italy

## INDICATIONS AND LIMITS OF SHOCK WAVES IN THE TREATMENT OF DIAPHYSEAL NON-UNIONS

S. Gigliotti, S. Russo, C. de Durante, O. Galasso  
University of Naples Federico II, Naples, Italy

### Introduction

The experience of five years in the treatment of non-unions by ESWT allows us to discuss the indications of this technique with reference to type of non-unions, to stability between fragments, to presence of internal or external devices.

### Method

From January 1995 to September 1999 we have treated by shock waves 166 diaphyseal long bone non-unions (43 cases of tibia, 30 of femur, 18 of humerus, 20 of cubitus, 19 of radius, 8 of fibula, 9 of clavícula, 13 of metacarpal and metatarsal, 3 of phalanx). Average period of non-union was 14 months and minimum follow-up was 6 months. We have used an electromagnetic lithotripter (STORZ MEDICAL AG) with an „in-line“ radiographic and ultrasound localisation of non-union area. From 4 to 6 sessions of treatment were applied; in each session 4000 impulses were shot at an energy flux density from 0.5 mJ/mm<sup>2</sup> to 1 mJ/mm<sup>2</sup>.

### Results

Results were: total fusion in 67% of cases, partial fusion in 19% of cases and no fusion in 14% of cases. In non-unions treated by plates we have recorded an incidence of partial fusion greater than in non-unions treated by external devices or medullary nail because of impossibility to hit the circumference of bone totally with focal point pressure field. Good results we have recorded in cases of non-unions of legs treated by functional cast bracing or by walking cast after shock wave treatment. No satisfactory results we have recorded in humeral non-union not surgically stabilised before ESWT because of impossibility to achieve an adequate stability by casting. Presence of medullary nail does not prevent treatment but it is necessary to focalise the shock waves on cortical bone and results improve if the static fixation is converted to a dynamic static 1-2 months after ESWT.

3<sup>rd</sup> Congress of the International Society for Musculoskeletal Shock Wave Therapy (ISMST)  
01.-03.06.2000, Naples, Italy

## HIGH ENERGY SHOCK WAVES FOR PAIN MANAGEMENT IN ORTHOPAEDICS – A TWO YEAR FOLLOW-UP IN 899 CASES

W. Brunner, R. Thüringer, G. Ascher, Ch. Maluche, F. Kellner, A. Neuking, A. Solleder, F. Schmidt-Hoensdorf, K. Vetter  
Orthopaedic Doctors, various cities, Germany

From 01/96 to 12/96 899 patients who had already undergone thorough conservative treatment without any relief or were already operated were treated with an average of 3 sessions (each about 1500 shots) of high energy shock waves in 7 different orthopaedic practices. Indications were tennis/golfer elbow, plantar spur, achillodynia, insertion tendinitis and calcifications of the shoulder as well as trochanteric tendinosis and pseudarthrosis. The intensity of pain was evaluated according to a visual scoring system before, 3 months and 2 years after treatment. 29% were absolutely pain free, a further 34.3% reported of a pain reduction of at least 50%. 56 patients (6.3%) had to undergo surgical treatment in spite of the shock wave application. The average pain intensity (maximum 10) was 7.4 before therapy, 3.9 after 3 months and 3.2 after two years.

### Conclusion

In nearly 2/3 a significant and durable pain reduction can be achieved in above named indications. Therefore the application of high energy shock waves should be recommended before considering surgery.

3<sup>rd</sup> Congress of the International Society for Musculoskeletal Shock Wave Therapy (ISMST)  
01.-03.06.2000, Naples, Italy

## THE MANAGEMENT OF OSTEONECROSES BY SHOCK WAVE TREATMENT

S. Gigliotti, O. Galasso, A. Carretta, E. Marlinghaus\*, U. Hagelauer\*  
University of Naples Federico II, Naples, Italy  
\*STORZ MEDICAL AG, Kreuzlingen, Switzerland

The pathologic process whereby bone develops cysts, sclerosis, flattening, sequestra, and secondary arthrosis variously has been termed osteonecrosis, avascular necrosis, and ischemic necrosis. The osteonecrosis is usually considered to have an ischemic origin. Several bone districts can be afflicted with osteonecrosis; however, certain bones frequently develop this disease. These bones have a vascular system that is at high risk of causing necrosis: the vascular bed is of terminal type or it is usually insufficient for the bone.

The idea of applying shock waves to osteonecrosis arises from our experience in treating carpal scaphoid pseudarthrosis. Some cases showing segmental necrotic areas within the proximal pole of the bone were treated. After shock waves we observed in the above-mentioned necrotic areas, signal normalisation both in T1 and T2 post-treatment Magnetic Resonance Imaging (MRI). The result was interpreted as a consequence of a blood flow increase in the terminal type vascular bed of such bones.

To verify whether shock waves could be useful in any necrotic lesion of bones, we started to treat some cases of Kienbock's disease by such technique. The results achieved induces us to extend the study even to bigger bones and, therefore, we started to treat femoral heads and other bones affected by necrosis.

Since 1997, 116 patients suffering from various osteonecrosis have been treated. The distribution of the osteonecrosis was as follows: 94 femoral head necrosis, 7 necrosis of the astragalus bone, 14 Kienbock's disease, 1 necrosis of the tarsal scaphoid bone. 49 from the 94 patients suffering from femoral head osteonecrosis have been subjected to a two year follow up, all the others had a minimum follow up of six months.

The shock wave treatment of the femoral head osteonecrosis showed the best results: the 85% of the patients referred complete recovery of disease. Results let us consider that the shock wave therapy is a very effective treatment of the femoral head osteonecrosis at early and intermediate stage. Satisfactory results were obtained treating the Kienbock's disease whereas it is hard to evaluate the efficacy of the shock waves on the necrosis of the astragalus or tarsal scaphoid because of the few patients treated. However, first results seem to be interesting. A larger experience is required to propose this technique to treat necrosis of the astragalus and tarsal scaphoid bones.

3<sup>rd</sup> Congress of the International Society for Musculoskeletal Shock Wave Therapy (ISMST)  
01.-03.06.2000, Naples, Italy

## THE IN VIVO CAVITATION MEASUREMENT

S. Russo, O. Galasso, E. Marlinghaus\*, U. Hagelauer\*, J. Mayer\*  
University of Naples Federico II, Naples, Italy  
\*STORZ MEDICAL AG, Kreuzlingen, Switzerland

Cavitation looks like an important mechanism of action of shock waves on tissues. This phenomenon is defined as the movement of bubbles containing gas or vapor in a fluid. Cavitation is well known as a powerful mechanism of material damage from the beginning of this century when it was discovered that it causes surface erosion and failure of ship propellers. Due to the pressure and shear loads next to propagation front of shock waves cavitation bubbles develop. When a subsequent shock wave hits a cavitation bubble, the increased external pressure causes the bubble to shrink, whereby the latter absorbs part of the sonic energy. If the excitant forces are large enough, the bubble collapses, thereby releasing part of the energy stored in the bubble to the medium as a new acoustic wave: a water jet of high velocity preferable towards a nearby surface develops.

The cavitation bubbles have to date only been detected in vitro on human tissues. The in vivo formation of cavitation bubbles and their collapse have been now registered during shock wave treatment. Authors were able to detect the formation of cavitation bubbles, the power ( $\text{mJ}/\text{mm}^2$ ) at which the cavitation develops and its consequence on clinical success rate. Factors that could influence the formation of bubbles have also been investigated.

The authors detected cavitation both in soft tissues and in the bone, while cavitation bubbles have not been observed on the cortical bone. The maximum energy ( $1.226 \text{ mJ}/\text{mm}^2$ ) of the device employed (MODULITH SLK - STORZ MEDICAL AG) was not able to determine the formation of cavitation bubbles at a depth that was more than 2.5 cm from the surface of the bone.

The formation of cavitation bubbles has been demonstrated depending strongly on the water concentration in tissues, on the ambient medium in which shock waves propagate, and on time between different shock wave applications. The absorption coefficient of the bone has also been detected.

Congress of the International Society for Musculoskeletal Shock Wave Therapy (ISMST)  
24.-25.05.2001, Berlin, Germany

## EXTRACORPOREAL SHOCK WAVE THERAPY VERSUS SURGICAL TREATMENT IN CALCIFYING TENDINITIS AND NON CALCIFYING TENDINITIS OF THE SUPRASPINATUS MUSCLE

M. Haake<sup>1</sup>, M. Rautmann<sup>2</sup>, T. Wirth<sup>1</sup>

<sup>1</sup>Orthopaedic Department of the Philipps-University, Marburg, Germany

<sup>2</sup>Orthopaedic Department of Klinikum Mannheim, Faculty of Medicine, University of Heidelberg

**Abstract:** The authors performed a study to compare the short-term clinical outcome between three methods or failed conservative treatment of the supraspinatus muscle tendinitis, extracorporeal shock wave therapy (ESWT) and open or arthroscopical subacromial decompression.

60 patients treated by ESWT or treated surgically (14 open, 16 arthroscopically) were included and assessed preoperatively and 3 months postoperatively with the subjective shoulder rating system (SSRS score). Another parameter investigated was a cost analysis with emphasis on the time of unfitness for work.

There was a considerable score increase in all three groups three months after intervention with a change of 24 and 25 points in the surgical subgroups and of 14 points in the ESWT group. This led to 40% good/very good results in the open surgical group, 62% good/very good results in the arthroscopically treated group and 67% good/very good results in the ESWT group. The time of unfitness for work and costs for treatment were lowest in the ESWT group.

ESWT appears to be an effective and relatively inexpensive treatment for supraspinatus muscle tendinitis and should be considered before surgical treatment is employed.

**Keywords:** Extracorporeal shock wave therapy – ESWT – Open and arthroscopic subacromial decompression – Cost of illness

Extracorporeal shock wave therapy (ESWT) represents a new method of treating insertion tendopathies for cases unsuccessfully treated by conservative means; its value has not yet been definitely assessed. The literature differentiates between high and low energy applications, in which the division into different energy areas has been determined in a non-standardised way. Dahmen et al. [2] reported first, then Haist et al. [5], Loew et al. [8] and Rompe et al. [13] on ESWT treatment of insertion tendopathies and calcifying tendinitis with a success rate of 65% to 75%. As yet there have been no meaningful prospective placebo-controlled studies for treating insertion tendopathies of the shoulder. In the year 1996, the number of applications in the orthopaedic area, with an estimated 60.000 – 100.000 patients, has finally exceeded the number of applications of lithotripsy in urology.

Unsuccessful conservative treatment also was the prerequisite for indicating surgical treatment (OP) for tendinitis of the supraspinatus muscle by enlarging the supraspinatus passage through anterior acromioplasty according to Ellman or Neer [4, 9]. In cases with calcifying tendinitis the calcified area is optionally removed in addition. Basically both arthroscopic and open anterior acromioplasty are possible. Results for arthroscopic acromioplasty (in the literature: from 69% to 95% good results) are equivalent to those for the open technique [1, 10].

The aim of the study was to compare the clinical outcome of three different methods indicated for failed conservative treatment for supraspinatus tendinitis. Secondly, a cost analysis was performed with special view of the postoperative unfit for work.

### Material and methods

The patient population was made up of a total of 60 patients with a clinical picture of a chronic tendinitis of the supraspinatus muscle with or without calcifying tendinitis. The key objective criterion for clinical success was the Subjective Shoulder Rating System (SSRS) 12 weeks after the operation [7, 16]. Data collection was carried out prospectively in a non-randomised patient population.

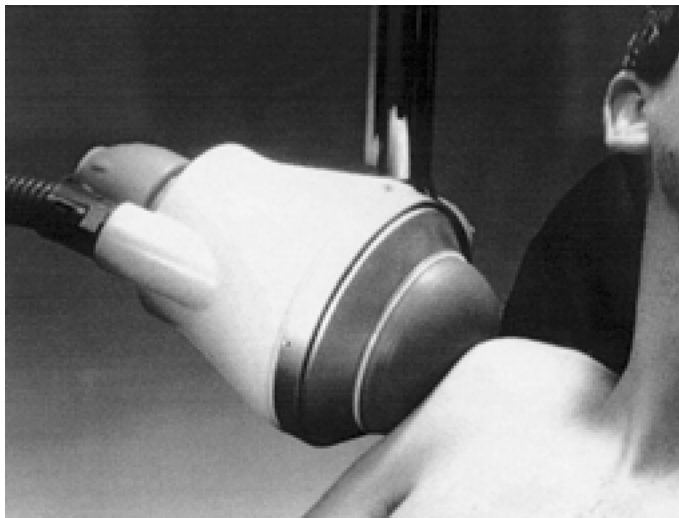

Fig. 1 : ESWT application to the right shoulder

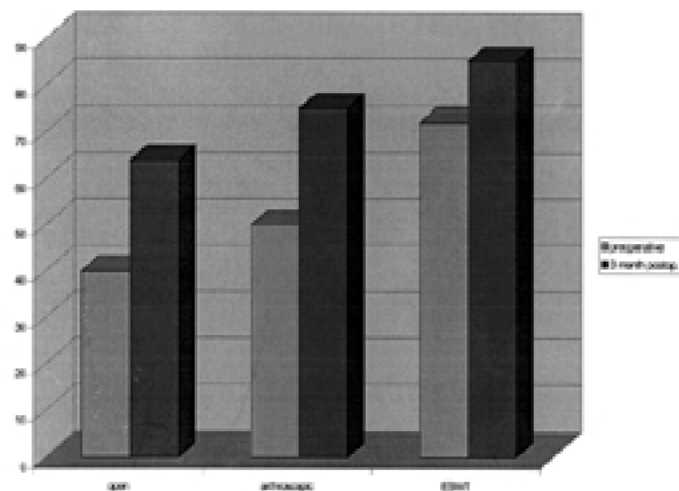


Fig. 2 : Change of SRSS-Score before and after the intervention

The indication for ESWT or OP was given analogously when patients had been conventionally treated without success at least 6 months before ESWT / OP. The treatment was only carried out in the case of isolated chronic tendinitis of the supraspinatus muscle or chronic tendinitis of the supraspinatus muscle with type 1 or 2 calcific deposits according to Gärtner [5] with a minimum diameter of 1 cm.

In the period from March to December 1997 30 patients with an average age of 49.7 years (min. 32, max. 64) underwent ESWT. On the other hand, 30 patients with an average age of 51.1 years (min. 40, max. 60) with the same diagnosis were surgically treated with an acromioplasty (14 open/16 arthroscopically) according to Ellman [4] or Neer [9] between 1995 and 1997. If the patient presented with a calcifying tendinitis an open acromioplasty with lime deposit dissection was carried out.

A modified Storz Minilith SL1 lithotripter (Storz Medical, Switzerland) was used for the ESWT. In the case of calcifying tendinitis the locating was carried out by axial view X-ray. Two treatments each of 2000 impulses of the energy flow density  $E+ = 0.35 \text{ mJ/mm}^2$  were administered a week apart. In the case of supraspinatus tendinitis the locating was implemented by inline ultrasound on the base of the tendon (Fig. 1). Depending on the pain tolerance the energy flow density used was  $E+ = 0.08\text{-}0.14 \text{ mJ/mm}^2$  without local anaesthetic, for 3 treatments a week apart, each of 2000 impulses.

Each set of clinical results was evaluated using the SSRS according to Wülker [7, 16] directly before and 12 weeks after the ESWT. A score greater than/equal to 80 points was rated a success. Also a score greater than/equal to 70 points was rated a success, when the score increased by 30 points after treatment. For the rest of the patients a score increase of at least 15 points was assessed as satisfactory, the remainder graded as poor.

Cost analysis included the actual costs of the hospital stay, the ESWT application, the postoperative or post ESWT rehabilitation costs and the indirect costs caused by the patient's inability to work.

## Results

The surgical subgroup (14 treated by open, 16 by arthroscopic acromioplasty) consisted of 24 patients with chronic supraspinatus muscle tendinitis and 6 patients with a calcifying tendinitis. 27 of these 30 patients were fully employed. The average preoperative SSRS-Score was 45 points (19-74 points). The ESWT subgroup contained 8 patients with a pure chronic tendinitis of the supraspinatus muscle and 22 with a calcifying tendinitis. All patients were fully employed. The preoperative SRSS-score averaged 72 points (57-86).

The postoperative change of the SSRS-score is given in figure 2. Patients who were operated on by an open procedure had a lower preoperative score than the other groups. The postoperative score was also lowest in the open surgery group. The score increase, however, was found to be almost equal in both surgical subgroups.

After evaluating the score, of the patients who had been operated on (open and arthroscopically) 57% (= 17 patients) had a good or very good, 20% (= 6 patients) a satisfactory and 23% (= 7 patients) a poor result. The evaluation of the ESWT patients resulted in 67% (= 20 patients) good or very good, 10% (= 3 patients) satisfactory and 23% (= 7 patients) poor results. Fig. 3 illustrates the success rate of the three subgroups. The radiological disintegration rate of the lime depot was 45% 12 weeks after ESWT, and 83% after the operation.

Due to the different values in the average SSRS pre-treatment score each minimum and maximum pre treatment score was ascertained for both populations. The score in the ESWT group lay between 57 and 86 points, in the surgical group between 19 and 74. By forming the points overlap from both populations those patients who showed a minimum pre-score of 57 points and a maximum pre-score of 74 points could be identified. It transpired that in the shock wave group 20 patients and in the surgical group 6 patients fulfilled the aforementioned terms of reference. A random generator (statistics program SPSS) was used to select six out of the 20 ESWT patients with an appropriate pre-score. In this way a comparison could be made between the two resultant subgroups.

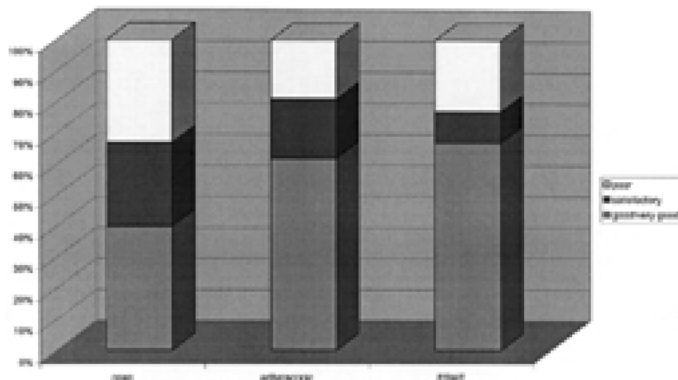


Fig. 3: Distribution of clinical results in all subgroups

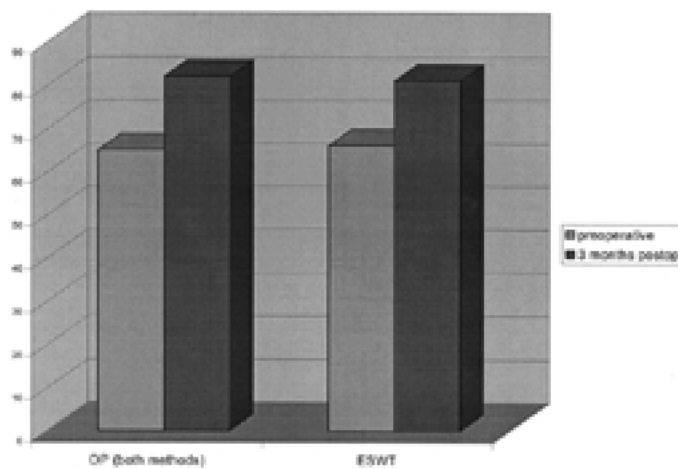


Fig. 4: Pre- and postoperative SSRS-Score of the statistically adjusted subgroups

After this streamlining there was a success rate of 67% good and very good results (an increase from 65 to 82 points) in the surgical subgroup, with an unaltered success rate in the ESWT subgroup. Fig. 4 illustrates the SSRS-Score of these statistically selected comparable subgroups.

The average overall cost per patient in the surgical subgroup was EUR 13.260 or EUR 23.400 (depending on how unfitness for work was calculated [3, 11]). Of this EUR 3.150 was related to the hospital stay including the operation, EUR 390 to outpatient physiotherapy, and EUR 9.710 or EUR 19.440 to the period when the patient was unfit for work. In the cost analysis average overall costs in the ESWT subgroup were calculated at EUR 2.670 or EUR 4.420 per patient. Of this EUR 658 was apportionable to the shock wave therapy itself, EUR 263 to outpatient physiotherapy and EUR 1.750

or EUR 3.500 to the costs of being unfit for work. The portion of the costs caused by the patient being unfit for work was 2/3 of the overall costs.

## **Discussion**

Arthroscopic and open acromioplasty have become standard procedures for surgically treating the supraspinatus muscle tendinitis. Both operations have been reported to be equal with regards to the clinical outcome with a generally shorter rehabilitation time following the arthroscopic procedure [4, 12, 14, 15]. The arthroscopic procedures are known to allow earlier rehabilitation with a considerable shorter time off work [1]. Frequently it can be performed as an outpatient procedure [4].

The ESWT application has been performed on an outpatient basis as well, and a mean off work time of 7.7 days was recorded. All but three patients treated arthroscopically could return to work within 6 weeks after the operation. The average time of unfitness for work in the group treated by open surgery averaged 11 weeks. These data show that ESWT treatment can be an efficient method with short rehabilitation time. Further, a short follow up time is justified when unfitness for work is a key outcome parameter like in this study.

The clinical results of our surgical subgroups appeared to be rated worse than other results presented in the literature. The main reason for that is the follow-up time of 3 months. It is known that the clinical outcome improves further with time. Nutton [10] showed, that there was an improvement of the UCLA-Score from a 28% success rate at 3 months to 85% success rate after 1 year following arthroscopic subacromial decompression. With this background, the results presented in this study are well in accordance with the published results for both open and arthroscopic subacromial decompression.

The clinical results twelve weeks after ESWT, measured on the SRSS score, showed a good and very good result in two thirds of cases. In comparison the radiological disintegration rate was only 45% versus 83% in the surgical groups. Both results were well within the range of the data published so far on the 12 weeks success rates of ESWT [8, 13]. Also for ESWT a further slight increase in the clinical score evaluation can be expected after one year [13].

The clinical results in the ESWT group seem to be more favourable than in the surgical groups. However, the homogeneity of the groups varies with a tendency to lower preoperative scores in both surgically treated subgroups. By statistical adjustment comparable patients could be identified and separately analysed. These patients exhibited almost identical scores after surgical or ESWT-procedure. We conclude that both the ESWT and the surgical procedures have similar potential to successfully treat the chronic tendinitis of the supraspinatus muscle.

A directly randomised comparison would be desirable from a methodical point of view. Although both populations were tested prospectively for themselves, the direct comparison can only take place retrospectively for the reason that patients are not prepared to be also randomly picked in the operation group for a study with the choice of a shoulder operation versus ESWT.

The cost calculation also supports the concept of applying ESWT to patients with chronic supraspinatus tendonitis before surgery may be considered. Since the time the patient is unfit for work is the most costly economic factor, the ESWT treatment may have the first treatment priority in such cases. This study showed that any surgical intervention is more expensive due to the longer rehabilitation phase.

We conclude that there is a place for ESWT in the treatment of supraspinatus muscle tendinitis with or without calcification particularly for patients with a sufficient range of motion in the shoulder. For cases with reduced joint motion due to capsular adhesions we recommend a primary surgical approach.

## References

1. Checron AJ, Dennis MG, Zuckerman JD (1998) Open versus arthroscopic decompression for subacromial impingement. A comprehensive review of the literature from at least 25 years. *Bull Hosp Jt Dis* 57: 145 - 151
  2. Dahmen G, Meiss L, Nam V, Franke R, Gonchars V (1992) Extrakorporale Stoßwellentherapie (ESWT) im knochenahnen Weichteilbereich an der Schulter- Erste Therapieergebnisse *Extracta Orthop* 15: 25 - 29
  3. De Girolamo, G (1991) Epidemiology and Social Costs of Low Back Pain and Fibromyalgia *Clin J Pain*; Vol 7, Suppl 1: 1 - 27
  4. Ellman H, Kay SP (1991) Arthroscopic Subacromial Decompression for Chronic Impingement. *J. Bone Joint Surg* 73-B: 395 - 398
  5. Gaertner J (1993) Tendinosis calcarea – Behandlungsergebnisse mit Needling. *Z Orthop* 131: 61 – 469
  6. Haist J, Steeger D, Witzsch U, Bürger R, Haist U (1992) The extracorporeal shockwave therapy in the treatment of disturbed bone union. 7th Int Conference on Biomedical Engineering, Singapore, 222-224
  7. Kohn D, Geyer M (1997) The subjective shoulder rating system. *Arch Orthop Trauma Surg* 116: 324-328
  8. Loew M, Daecke W, Kusnierczak D, Rahmanzadeh M, Ewerbeck V (1999) Shock-wave therapy is effective for chronic calcifying tendinitis of the shoulder. *J Bone Joint Surg* 81-Br: 863-867
  9. Neer C (1972) Anterior acromioplasty for the chronic impingement syndrome in the shoulder. *J Bone Joint Surg*, 54-A: 41 - 50
  10. Nutton RW, McBirmie JM, Phillips C (1997) Treatment of chronic rotator cuff impingement by arthroscopic subacromial decompression. *J Bone Joint Surg* 79-B: 7 3 - 7 6
  11. Pförringer W (1997) Rückenschmerz-, Costofillness"-Studie. *Z Orthop* 135; Suppl: Abstract 91
  12. Rockwood, CA, Lyons, FR (1993) Shoulder Impingement Syndrome: Diagnosis, Radiographic Evaluation and Treatment with a Modified Neer Acromioplasty. *J Bone Joint Surg* 75-A: 409 - 423
  13. Rompe J-D, Rumler F, Hopf C, Nafe B, Heine J (1995) Extracorporeal shock wave therapy for the calcifying tendinitis of the shoulder. *Clin Orthop* 321: 196 - 201
  14. Roye RP, Grana WA, Yates CK (1995) Arthroscopic subacromial decompression: two – to seven year follow-up. *Arthroscopy* 11: 301 - 306
  15. Sachs RA, Stone ML, Devine S (1994) Open vs. arthroscopic acromioplasty: A prospective randomized study. *Arthroscopy* 10: 248 - 254
  16. Wülker, N, Kohn, D, Grimm, C (1991) Bewertung der Schulterfunktion mit unterschiedlichen Scores. *Orthop Praxis* 12: 750 - 754
- Received September 18, 2000 / Accepted in final form December 02, 2000

### Comparaison entre la lithotripsie extracorporelle par ondes de choc (ESWT) et le traitement chirurgical de la tendinite calcifiante et non calcifiante du muscle du sus-épineux

**Résumé:** Les auteurs ont mené une étude sur le résultat clinique à court terme du traitement de la tendinite du muscle sus-épineux après échec du traitement conservateur à l'aide de trois techniques: la lithotripsie extracorporelle par ondes de choc (ESWT), la décompression sous-acromiale à ciel ouvert ou par arthroscopie. Le groupe étudié comportait 30 patients traités par ESWT et 30 patients traités par chirurgie dont 14 à ciel ouvert et 16 par arthroscopie. La tendinite a été évaluée avant et 3 mois après l'intervention à l'aide du score SSRS, un système de cotation subjective pour l'épaule (score SSRS : subjective shoulder rating system). Un autre paramètre examiné était l'analyse des coûts mettant l'accent sur la durée d'incapacité de travail. Une amélioration considérable du score SSRS a été constatée trois mois après l'intervention dans les trois groupes, avec une évolution de 24 et 25 points dans les sous-groupes chirurgicaux et de 14 points dans le groupe ESWT. On a conclu à 40 % de bons/très bons résultats dans le groupe traité par chirurgie à ciel ouvert, 62 % de bons/très bons résultats dans le groupe traité par arthroscopie et 67 % de bons/très bons résultats dans le groupe ESWT. La durée de l'incapacité de travail et les coûts de traitement étaient les plus faibles dans le groupe ESWT. La lithotripsie extracorporelle par ondes de choc semble être un traitement efficace et relativement bon marché de la tendinite du muscle sus-épineux et devrait être envisagée avant de recourir au traitement chirurgical.

**Mots clés:** Lithotripsie extracorporelle par ondes de choc – ESWT – Décompression sousacromiale – Coût de la maladie

